DUPLICATE
HX00020303

VANCROFT STUD

RK522 H58

Columbia University
in the City of New York
School of Dental and Oral Surgery

Reference Library

Digitized by the Internet Archive
in 2010 with funding from
Columbia University Libraries

http://www.archive.org/details/veterinarydenta00hine

VETERINARY DENTAL SURGERY,

FOR THE USE OF

STUDENTS,

Practitioners and Stockmen.

—BY—

T. D. HINEBAUCH, M. S., V. S.,

Professor of Veterinary Science at Purdue University,
Lafayette, Indiana.

ILLUSTRATED.

PUBLISHED BY THE AUTHOR.

LAFAYETTE, INDIANA.
1889.

Dent.
27.23116

Entered according to Act of Congress, in the year 1889, by
T. D. HINEBAUCH,
In the office of the Librarian of Congress, at Washington, D. C.

RK522
H58

CHICAGO PRINTING COMPANY,
PRINTERS AND BINDERS,
158 & 160 S. CLARK ST., CHICAGO.

CONTENTS.

PAGE.

CHAPTER I.

ANATOMY OF THE SUPERIOR MAXILLA — Pre-Maxilla and Inferior Maxilla—Sinuses of the Head..... 7

CHAPTER II.

TEETH—Their Structure and Composition; Dentine; Enamel; Cement—Kinds of Teeth; Incisors, Canine and Molars—Development of the Teeth..... 15

CHAPTER III.

TEMPORARY DENTITION OF THE HORSE, OX, DOG AND PIG..... 31

CHAPTER IV.

ABSORPTION OF THE DECIDUOUS TEETH..... 45

CHAPTER V.

PERMANENT DENTITION OF THE HORSE AND OX—Dentition Tables of the Horse and Ox..... 50

CHAPTER VI.

DISEASES DUE TO DENTITION—Symptoms and Treatment..... 61

CHAPTER VII.

CARIES OF THE TEETH—Forms, Symptoms, Results and Treatment..... 72

CHAPTER VIII.

DENUDING OF THE TEETH..... 88

CHAPTER IX.

EXOSTOSES—Their Nature, Cause, Symptoms and Treatment..... 94

CHAPTER X.

FOREIGN SUBSTANCES—Their Source, Symptoms and Treatment—Fractures of the Teeth; how caused; means of effecting their removal..... 115

PAGE.

CHAPTER XI.

Dental Cysts 124

CHAPTER XII.

Tartar—How formed; its effect upon the Teeth—Lampas; Causes, Symptoms and Treatment 132

CHAPTER XIII.

Projecting Teeth in Horses, Sheep and Pigs—Their Cause, Results and Treatment 139

CHAPTER XIV.

Long, Sharp and Projecting Edges—Their Cause, Effect and Removal—Special Operations—Side Lining—Shying—Runaways—Method of Operating for Each 154

CHAPTER XV.

Diseases of the Lower Jaw—Injuries from Heavy Curb Bit 168

CHAPTER XVI.

Cribbing—Causes, Effects and Treatment 174

CHAPTER XVII.

Alveolar Abscesses—Their Formation, Progress, Symptoms and Treatment 181

CHAPTER XVIII.

Tumors of the Gums—Their Character, Causes and Treatment—Epulis 189

CHAPTER XIX.

Nasal Gleet—Causes, Symptoms and Treatment—Trephining—Steps in the Operation—After Treatment 195

CHAPTER XX.

Osteo Porosis 210

CHAPTER XXI.

Filling Horses' Teeth 224

CHAPTER XXII.

Determination of the Age of the Horse, Ox, Pig, Sheep and Dog 240

PREFACE.

It is owing to the scarcity of literature devoted to the principal operations of veterinary dentistry, and the belief that such a work will be favorably received by the veterinary profession at large, that the author attempts this volume. With an extended experience as a veterinary dentist, and scattering articles which have appeared upon the subject from time to time, the bringing together of these into a single volume cannot fail to be productive of good results, in the placing upon a scientific basis this most neglected division of veterinary surgery.

It is designed for practical stockmen as well as for students and practitioners, hence technical terms have been avoided as much as possible.

Scientific veterinary dentistry is yet in its infancy. While operations upon the teeth of horses have been performed for many years, the humane method of handling horses' mouths and operating for diseases of that cavity has been confined to the last fifteen years.

The author has drawn from various works, notably those of Williams, Percival, Owen, Chauveau, Clark and Parreidt. Also others which have received credit where the quotations appear.

The author is especially indebted to Dr. C. E. Sayre, D. V. S., Professor of Dental Pathology in the Chicago Veterinary College, for valuable assistance, and to Dr. Anderson, D. V. S., of Louisville, Ky., a graduate of the Chicago Veterinary College, for the valuable chapter on Osteo Porosis.

Professor Windle, of Earhlam College, prepared most of the drawings from original specimens.

Sharp & Smith, of Chicago, Ill., furnished the cuts of instruments, with the exception of those used in filling teeth; these were kindly furnished by the S. S. White Dental Manufacturing Co., of Philadelphia. The Photo Engravings were made by the Photo Engraving Co., of New York.

The object of the author in presenting this volume is to bring the subject more clearly before the public, and inculcate in them a true conception of its importance. No branch of veterinary science has been so universally ignored as that pertaining to the management and preservation of the teeth of the domestic animals.

T. D. HINEBAUCH.

Purdue University, Lafayette, Ind., Oct. 1, 1889.

ERRATA.

Page 54, line seven from below should read:

Two Years...T T T O P P T P P O

CHAPTER I.

ANATOMY OF THE SUPERIOR MAXILLA, THE PRE-MAXILLA AND INFERIOR MAXILLA. SINUSES OF THE HEAD.

In no branch of Veterinary Science is it more important to possess an accurate knowledge of the conditions which are present in a state of health as well as disease, than in the care and treatment of the teeth. It is only by a thorough knowledge of the appearance of an organ during health, that the practitioner is able to recognize a diseased condition. And in order that he may remedy that defect and restore the structure to a healthy state, it is necessary that he should thoroughly understand the nature and extent of the disease.

ANATOMY.

In discussing the anatomical relations of the bones of the face and head of the horse only those will be mentioned which are directly involved in diseases of the teeth. These are the superior maxilla, the pre-maxilla and the inferior maxillary bones.

The superior maxilla (Fig. 1-4) is situated at the side of the face, irregular in form somewhat triangular, and elongated from before backwards. It affords

lodgment for the molar teeth and presents two surfaces, two borders and two extremities. The external surface is convex and smooth and presents an elongated horizontal ridge opposite the fourth and

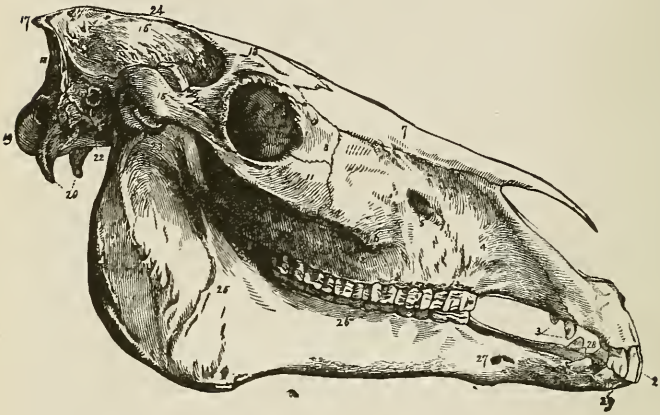

FIG. 1.

LATERAL VIEW OF THE HORSE'S SKULL.

1, Pre-maxilla bone; 2, Upper incisors; 3, Upper canine teeth; 4, superior maxillary bone; 5, Infra-orbital foramen; 6, Superior maxillary spine; 7, Nasal bones; 8, Lachrymal bone; 9, Orbital cavity; 10, Lachrymal fossa; 11, Malar bone; 12, Upper molar teeth; 13, Frontal bone; 15, Zygomatic process; 16, Parietal bone; 17, Occipital protuberance; 18, Occipital crest; 19, Occipital condyles; 20, Styloid processes; 21, Petrous bone; 22, Basilar process; 23, Condyle of inferior maxilla; 24 Parietal crest; 25, Inferior maxilla; 26, Inferior molars; 27, Anterior maxillary foramen; 28, Inferior canine teeth; 29, Inferior incisor teeth.—*Chauveau.*

fifth molar teeth. Above, this ridge is continuous with the Zygomatic spine. The large opening of the infra-orbital canal (Fig. 1-5) opens on the face near the middle of the upper surface. This gives

exit to the facial division of the fifth nerve and a branch of the superior dental artery. The internal surface forms the sides and most of the floor of the nasal cavity. At the posterior part of this surface is a deep excavation which helps form the maxillary sinus. The inferior or palatine surface forms the greater part of the floor of the nasal fossa by which it is separated from the mouth. The under part of the palatine process is furrowed by numerous small grooves and a deeper groove near its outside border which lodges a branch of the palatine artery, being separated from the molar teeth by the alveolar process.* The superior border is thin, convex, grooved and serrated to articulate with the nasal, pre-maxilla, lachrymal and malar bones. The inferior border is thick and strong, and is divided into quadlateral cavities which correspond to the number of molar teeth, and in which they are lodged. These cavities are known as alveoli. The alveolar tuberosity, a rugged eminence, is located just back of the last alveolus. Anterior to the first alveolus the border is thin and covered by soft tissues helping to form the interdental space. The posterior extremity is thickest and represents the alveolar tuberosity, in the interior of which the maxillary sinus is prolonged. Within this eminence, is a wide and deep excavation known

*Sometimes in grasping a molar tooth with the forceps, this artery becomes wounded and may prove troublesome to the operator unless the hemorrhage can be checked.

as the maxillary hiatus, and which contains three foramina; the first leads to the palatine groove giving exit to the palatine artery, the second enters the maxillary sinus passing along the roots of the molar teeth and dividing into two branches; one short and wide which opens on the external surface of the bone on a level with the third molar tooth, the other continues along the canal of the bone to the roots of the incisor teeth. The third, the palatine canal, enters the nasal chambers and gives passage to blood vessels and nerves. The anterior extremity of this bone with the posterior extremity of the pre-maxilla forms a cavity in which the canine tooth is lodged.

The pre-maxilla bone (Fig. 1-1) occupies the anterior extremity of the face, and consists of a thick portion and two processes. The thick portion presents three surfaces, the external or labial, which is smooth and convex; an internal, which is roughened to articulate with its fellow on the opposite side, and is traversed by a fissure, which forms with the bone of the opposite side, the foramen incisivum, for the passage of the palato-labial artery; and an inferior, which is smooth and slightly concave and shows the continuation of the palatine fissure which opens into the foramen incisivum. Between the external and inferior surface is a thick border which is divided into two parts, an anterior and posterior; the anterior contains three alveoli, which receive the incisor teeth.

Posterior, it is thin and completes the interdental space. (In the Ruminantia the pre-maxilla is broad, its inferior surface flat and destitute of alveolar cavities, hence it possesses no incisor teeth but instead is covered by a dense cartilaginous pad, against which the lower teeth press the food while the animal is grazing). The processes are external and internal. The external is the largest and longest, its outer surface convex and smooth, its inner surface being covered by the mucous membrane of the nose. The internal process is flattened and thin, the superior surface forming part of the floor of the nasal fossa. The inferior surface forms part of the hard palate.

The inferior maxilla (Fig. 1–25) is a large V-shaped bone situated below the upper jaw and with which it articulates. It consists of two symmetrical branches which are flattened on both sides, wider posteriorly than anteriorly, curved upward at the upper third and joined anteriorly so as to leave a space, which is known as the intermaxillary space. The external surface is smooth anteriorly and rough posteriorly. The internal surface is smooth and flat anteriorly, and rough and concave posteriorly. It presents a large opening, the inferior dental foramen, which passes through the bone below the roots of the molar teeth. The superior or alveolar border is straight anteriorly and concave posteriorly. The first contains six alveoli for the lower molars. The

second, which is thinner, is somewhat roughened for muscular attachment. The inferior border is divided into two portions, straight and curved, the latter being convex and thick, the first rectilinear, thick and rounded in the young animal, but becoming sharp with age. The union of the two forms the angle of the jaw. The posterior extremity presents two eminences, a coronoid process anteriorly and a condyle posteriorly. These eminences are separated by a deep notch, the sigmoid or corono-condyloid notch. The anterior portion of the inferior maxilla is a single piece, flattened above and below and widened anteriorly. The anterior border is convex and contains six alveoli (in Ruminantia eight), which receive the inferior incisor teeth. Just posterior to the incisor teeth are two cavities, one on either side, which contain the canine teeth. On the external surface, about midway between the canine and first molar teeth, is a foramen (Fig. 1–27), the inferior orifice of the dental canal, which transmits the inferior dental artery and inferior division of the fifth pair of nerves, which supply the teeth with sensation. At this place the bone is constricted to form a neck. Superiorly there is a ridge, more or less sharp, which helps form the inferior interdental space.

SINUSES.

Sinuses are winding cavities in the bones of the face communicating freely with each other, and with

the nasal fossa of which they may be considered as prolongations. There are four on each side; viz.: The frontal, the maxillary, the sphenoidal, and the ethmoidal. These cavities are filled with air in their normal state, giving increased volume to the head without increasing its weight. In this manner wide surfaces are furnished for the insertion of muscles which in this region are large and numerous.

The frontal sinus is situated at the inner side of the orbit, presenting very irregular walls which are formed by the frontal, (Fig. 1–13), nasal, (Fig. 1–7), lachrymal, (Fig. 1–8), externally and internally, the ethmoid and superior turbinated bones.

The frontal sinus communicates freely with the maxillary sinus by a vast opening through the thin bony partition which separates the two sinuses. A vertical bony plate, perforated separates this sinus from that of the opposite side, but is always imperforate.

The maxillary sinus formed beneath the orbit, by the superior maxillary, (Fig. 1–4), malar, (Fig. 1–11); lachrymal, (Fig. 1–8), externally and internally by the ethmoid and inferior turbinated. This is the largest of the sinuses, and is divided into two compartments by a ridge, which contains the superior dental canal, into an internal small and shallow, and continuous with the sphenoidal, and communicating with the ethmoidal sinus, and an external which is

large and divided into two chambers by a transverse plate of bone which always remains perfect through life, completely isolating the anterior chamber. This plate of bone is usually opposite the space between the fourth and fifth molar teeth, so that by trephining over that region an opening will be made in both compartments. The posterior of these chambers, sometimes known as the superior maxillary sinus, is continued backwards to the alveolar tuberosity and contains the roots of the last two molar teeth. The anterior division, sometimes called the inferior maxillary sinus is the smaller of the two and has the roots of the fourth, occasionally the third molar teeth projecting into it.

The sphenoidal sinus is small and formed by the sphenoid and palatine bones. It is subdivided by incomplete partitions into several compartments.

The ethmoidal sinus the smaller of these cavities is a space included in the ethmoid bone. It communicates with the maxillary sinus.

CHAPTER II.

TEETH.

THEIR STRUCTURE AND COMPOSITION, DENTINE, ENAMEL, CEMENT — KINDS OF TEETH — INCISORS, CANINE AND MOLARS—DEVELOPMENT OF THE TEETH.

Teeth are firm substances implanted in and protruding from the maxillary alveoli, adapted for seizing, lacerating dividing and tricturating the food. They are the chief agents in the mechanical part of the digestive function. The teeth are intimately related to the food and habits of the animal. They vary in size, form, structure, position, attachment and number. But in all cases they are in correlation with the food and habits of the animal.

In Herbivora, the contacting surfaces of the molars are flat and rough for grinding the food. In Carnivora the molars are sharp and pointed to tear and crush the food. In Omnivora where both processes are used the teeth are mixed in their character.

A tooth is the most durable part of the animal body, and is frequently the sole remains of an animal.

Teeth consist of a cellular and a tubular basis of animal matter containing earthy particles, a fluid and a vascular pulp.

True teeth consist of three tissues which are characterized by different degrees of density. These are the Dentine, Enamel and Cement or Crusta-petrosa.

Dentine is a hard whitish yellow substance, forming the greater portion of a tooth, and consists of an organized animal basis disposed in the form of very minute tubes and cells, and of earthy particles. These earthy particles have a twofold arrangement, being either blended with the animal matter of the interspaces and parieties of the tubes and cells, or contained in a minutely and irregular granular state in their cavities. The density is due to the proportion of earthy material, 72 per cent being earthy matter and 28 per cent animal matter. The tubes and cells also contains a colorless fluid, "liquor sanguinis" which furnishes nutrition to this portion of the tooth. Dentine is non-vascular in the higher types of vertebrates, but in some of the lower forms the teeth are traversed by blood vessels. Fig. 2 shows a section through a molar tooth and illustrates the tubuli of the dentine.

The enamel is a thin layer of very dense tissue which covers the crown portion of the dentine, and and in some animals (the horse and Ruminantia) it dips into the table surface of the tooth to a great depth. It is very hard and white, taking a high polish during the process of mastication. It consists of 96.5 per cent of earthy matter and 3.5 per cent of

animal substance. When enamel is examined microscopically it present small prismatic hexagonal rods notched on their faces.

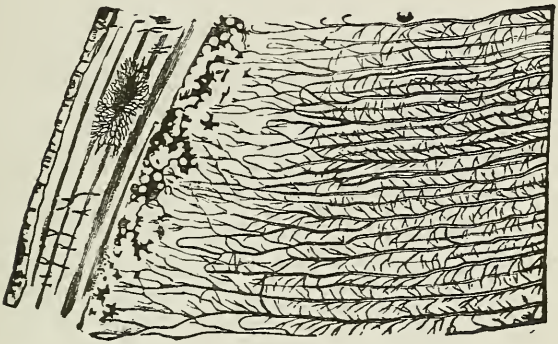

cc. bb. a.

FIG. 2.

aa, Dentine traversed by its tubuli; *bb*, Interglobular or nodular layer; *cc*, Cementum. *Chauveau.*

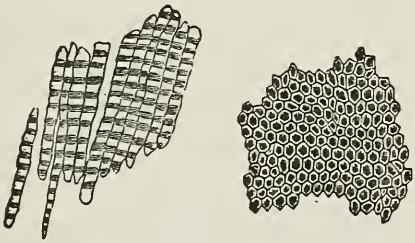

b. a.

FIG. 3.

a, Transverse section of enamel, showing its hexagonal prisms; *b*, separated prisms. *Chauveau.*

In simple teeth the whole free surface of the tooth is covered by enamel.

The cement covers the root portion of the den-

tine. It commences at the neck of the tooth, in very thin layers, and continues to increase in thickness toward the apex of the root, and corresponds in texture to the bony framework of the same animal, and is traversed by vascular canals. Where natural cavities exist on the free portion of a tooth, as in the Herbivora, they are occupied by crusta-petrosa. The cementum being less dense than the enamel, it is worn away in the cavities of the tooth as fast as the projections of enamel are worn down, so that the grinding surface is retained during the life of the animal. The cementum has tubuli and cells resembling canaliculi and lacunæ of bones. Indeed their physiological use is the same. These tubuli connect with the dental fibers.

As age increases the cementum increases in thickness and may give rise to a bony growth or exostosis. Sometimes the teeth of young animals are affected by exostosis, which is due to an extraordinary development of the cementum, for it is this tissue that is always found in their growths.

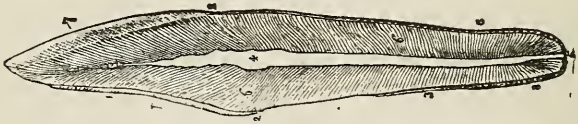

FIG. 4.

MAGNIFIED SECTION OF A CANINE TOOTH, SHOWING ITS INTIMATE STRUCTURE.

1, crown; 2, 2, neck; 3, fang or root; 4, pulp cavity; 5, opening by which the vessels and nerves communicate with the pulp; 6, 6, dentine, showing fibrous structure; 7, 7, enamel; 8, 8, cement. *Chauveau.*

The dental pulp (Fig. 4–4) is enclosed in the dentine and represents the shape of the tooth in a much diminished size. It consists of fribrilated connective tissue devoid of any elastic fibers. The dental pulp receives the blood vessels and nerves, and is covered by a thin membrane, composed of cells resembling cylinder epithelium which contain one or two nuclei. They are connected with one another and with the spindle cells, which lie just beneath them, by fine processes and also send processes into the dentinal canals. Although dentine is often very sensitive when exposed, there has never been any nerve fibers traced leading from the pulp into the dentine. The vessels of the pulp are very numerous and enter the tooth through the dentinal foramen at the apex of the root, traverse the pulp and at its upper surface form circles. This gives to the pulp the appearance of cavernous tissue. The nerves which are from the fifth pair (sensory), enter with the blood vessels and form numerous branches within the pulp.

As age advances the pulp and pulp cavity diminish in size, owing to the formation of osteo-dentine around that organ. This osteo-dentine is deposited by the pericementum which lines the pulp cavity as well as covering the root of the tooth. In old animals the pulp cavity is sometimes nearly obliterated, and is always smaller than in young animals.

The receding of the pulp and the closing of the

pulp cavity is most active at the time the tooth is first up and comes into wear.

Teeth are either simple or compound. Simple, as in the dog and cat, where the entire exposed surface is covered by enamel; and compound, as in the horse and ox, where two or more tissues come into wear.

For description, a tooth is divided into three portions; the crown, which is that portion above the gums; the grinding surface, being called the table; the cervix or neck, that part covered by the gums; and the fang or root, that portion which is inserted into the socket, or alveolus.

Teeth are of three kinds: Incisors, those occupying the anterior portion of the jaw; Canine, those occupying the interdental space; and Molars or grinders, those situated in the posterior of the jaw bone. In the horse there are 40 teeth; in Ruminants 32; in dogs 42, and in pigs 44. In the horse the dental formula will be:

Incisors, $\frac{3}{3}$—$\frac{3}{3}$; Canines, $\frac{1}{1}$—$\frac{1}{1}$; Molars, $\frac{6}{6}$—$\frac{6}{6}$ = 40

In the Ruminants the dental formula will be

Incisors, $\frac{0}{4}$—$\frac{0}{4}$; Canines, $\frac{0}{0}$—$\frac{0}{0}$; Molars, $\frac{6}{6}$—$\frac{6}{6}$ = 32

In the pig the dental formula will be:

Incisors, $\frac{3}{3}$—$\frac{3}{3}$; Canines, $\frac{1}{1}$—$\frac{1}{1}$; Molars, $\frac{7}{7}$—$\frac{7}{7}$ = 44

In the dog the dental formula will be:

Incisors, $\frac{3}{3}$—$\frac{3}{3}$; Canine, $\frac{1}{1}$—$\frac{1}{1}$; Molars, $\frac{6}{7}$—$\frac{6}{7}$ = 42

*"The incisors or front teeth in the horse are 12 in number, 6 in each jaw; the upper ones are the longest, their surfaces meeting those of the lower ones; in rare cases the former overlap," constituting a "parrot mouth." The central pair are the largest, the adjacent ones are called the middle, or lateral, while the outer ones which are the smallest are termed the corner incisors. [In Ruminants which have 8 incisors, the first pair are called centrals; the second

FIG. 5.

THEORETICAL SECTION OF THE DENTAL SAC OF A PERMANENT INCISOR IN THE HORSE.

a, proper membrane of the sac; *b*, Dental pulp.; *c*, Papilla of the external cavity of the tooth, a dependency of the enamel membrane; *d*, Epithelial layer of the dentine membrane; *e*, Cylindrical cells of the enamel membrane; *f*, Dentine; *g*, Enamel. The secretion of the cement is not supposed to have commenced. *Chauveau.*

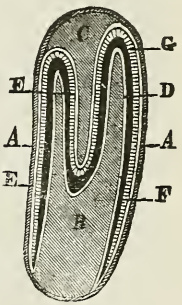

pair internal lateral; the third pair external lateral, and the fourth pair the corners]. The row of incisors form a curve, which is part of the so-called dental arch; the younger the tooth the greater the curvature, which gradully decreases with age. The anterior surface of a young incisor tooth presents a triangular shape, with the base at the table. Viewed laterally it is still triangular, but its apex is at the table. The table is therefore oblong, its long axis

*Strangeway.

following the line of the dental arch. As it wears it narrows laterally, but its short axis widens until in old age it is nearly round, what was the fang being in wear.

The free surface of an incisor tooth, excepting the table, is covered by a layer of enamel, (Fig. 6—4 A,) the fang which is a single process, being covered by crusta-petrosa. Towards the center of the table in a young tooth a second ring of enamel is visible (Fig. 4—4, B,) which is the mouth of a funnel-shaped cavity called the infundibulum. This cavity in the young animal is ovoid, its long axis following that of the table; it is lined by crusta-petrosa, which becoming stained by the food constitutes the so-called "mark." The space between the two tubes of enamel is filled up with dentine; hence the table is a compound one—*i. e.* all three of the dental tissues are in wear on it. The infundibulum or mark being conical in shape, wears with the tooth, becomes smaller and ultimately vanishes.

In the center the table in front of the mark is broader than behind it, and as the tooth wears it still broadens. In this space sometimes a spot is apparent which differs from the rest of the dentine; it is the osteo-dentine covering the pulp cavity. This object (Fig. 6–4, c,) has been termed the dental star. The corner teeth may have no posterior tables constituting *shell teeth;* rarely, they are absent in every tooth when we have a *shell mouth.*

The incisor *milk teeth* are whiter than the permanent ones, and have distinct necks (Fig. 6, 5.), the neck of the permanent tooth being imaginary.

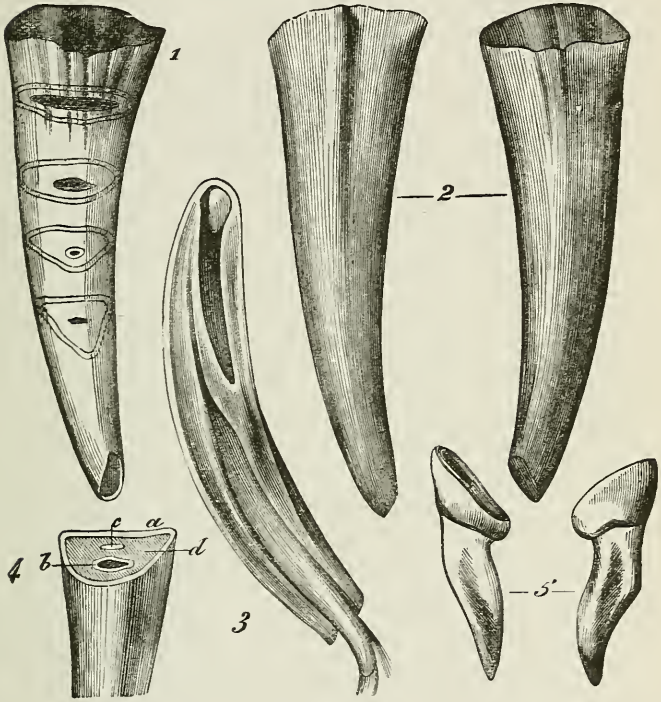

FIG. 6.

INCISOR TEETH OF THE HORSE. DETAILS OF STRUCTURE. 1, A tooth in which is indicated the general shape of a permanent incisor, and the particular forms successively assumed by the dental table in consequence of friction, and the continued pushing outwards of these teeth. 2, A virgin tooth anterior and posterior faces. 3, Longitudinal section of a virgin tooth intended to show the internal conformation and structure. 4, Transverse section for the same purpose. *a*, Encircling enamel; *b*, Central enamel; *c*, Dental star; *d*, Dentine. 5, Deciduous teeth. *Chauveau.*

Permanent incisors are convex anteriorly, the lower incisors have one, the upper, two grooves down the center of the body. These are filled with cementum, but are absent in old teeth.

[*"The follicle in which the incisor teeth are developed shows only two papillæ; one for the secretion of the dentine lodged in the internal cavity of the tooth, and hollowed into a cup-shape at its free extremity. The other is contained in the external *cul-de-sac* (Fig. 5, A. B. C.")].

The tushes, tusks or canine teeth, well developed in dogs and other carnivora, are simple teeth, four in number, two above and below. They rest in the interdental spaces, the lower being nearer the incisors than the upper ones; they are permanent and appear between the fourth and fifth year, sometimes a year in advance. The crown is somewhat conical, the base being at the gums. The external surface is convex and marked by several longitudinal lines; the internal surface presents on either side a sharp ridge, which separates it from the external. The crown terminates in a conical eminence; somewhat hollowed internally during growth, and bounded by a sharp ridge. When a tusk has been long in wear, the ridge disappears, and the internal surface becomes nearly smooth, and as the apex of the tooth becomes worn away, often a small mark appears but no second ring

*Chauveau.

of enamel. In the horse tribe as a rule canine teeth are only developed in the male; if they exist in the female they are rudimentary.

The molars or grinders are 24, 6 on each side, above and below. They are numbered from before backwards (Fig. 32), and like the incisors those of the upper jaw are the largest. A molar tooth is constructed on the same general plan as an incisor, but the contour of the various parts is much more irregular. There are generally two infundibula containing a large quantity of cementum, a layer of which also covers a greater part of the external enamel. (Fig. 7–AA).

The crown of the upper molars is somewhat cubic; their external surface presents two grooves running from table to root, the anterior being the deeper. The crown of the lower molars is narrower and longer than that of the upper ones and has only one groove. The inner surface of the upper molars is not so deep as the outer, while the inner surface of the lower ones is deeper. The two lower rows diverge towards the back of the mouth, while the two upper rows are rather convex externally.

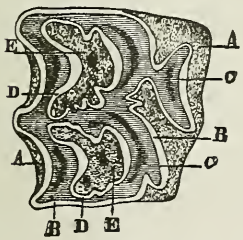

FIG. 7.

TRANSVERSE SECTION OF A HORSE'S UPPER MOLAR TOOTH.

a, external cement; *b*, external enamel; *c*, dentine; *d*, internal enamel; *e*, internal crusta-petrosa. *Chauveau.*

"A horse may have supernumerary molar or wolf teeth;

these are small, and placed on each side of the jaw, anterior to the first molars."

ANATOMY OF THE TEETH.

Teeth are papillæ of the mucous membrane of the gum which have undergone a characteristic development. During their growth they become fixed in their alveolar cavities which allow more or less motion during the process of mastication. While the process of development is going on part of the papilla is transformed into a layer of dentine, while the epithelium covering the papilla produces the enamel; the crusta-petrosa being added during the growth of the tooth, it being a product of that division of the periodental membrane which clothes the tooth.

The pulp represents the remainder of the dental papilla, around which the dentine was deposited, and is composed of a very vascular fibrilated connective tissue and is devoid of any elastic fibers. The outer layer of cells resemble columnar epithelium, which contains nuclei and fine grained protoplasm. These lie in direct contact with the dentine building up that part of the tooth. These cells send off long, fine branched processes into the dentinal canals, while their nucleated bodies lie on the surface of the pulp and form a connection between the cells of the pulp and dental tubes. All the vessels of the pulp enter the tooth through the dental foramen at the

apex of the root. The nerve fibers, which are sensory and from the fifth pair (trigeminous), enter with the blood vessels and by dividing form numerous branches, some of which become very fine and enter between the odonto blasts. Beyond this the nerve fibers cannot be traced and their mode of termination is as yet unknown.

The periodental membrane covers the root of the tooth and is connected with the osseous alveolus, in which the tooth is firmly lodged. In this membrane are developed the cemento blasts which build up the cementum, and also the osteo blasts which build up the walls of the alveolus. In addition this membrane also contains osteo clasts for the removal of portions of the walls of the alveolus. This process accommodates the changes which take place during the growth of the tooth. As the tooth enlarges and presses on the walls of the alveolar cavity, these osteo clasts absorb the walls of the alveolus, diminishing its thickness in proportion to the increase in size of the tooth. The osteo clasts also exert an influence in shaping the roots of the teeth, or in changing their form. The thickness of the membrane varies very much in different animals and around different teeth of the same animal. It is thickest in the young animal, gradually decreasing as age advances.

The periodental membrane always closely surrounds the root or fang and fills the alveolar cavity.

It also surrounds the body of the tooth to the neck or cervix.

During the growth of the periodental membrane it becomes closely allied to the surface of both the cementum and the bone. The fibrous elements fix and retain the tooth in its position. These fibers forms the bulk of the tissue of the membrane and have their ends fixed in the cementum of the tooth on one side and in the bone which forms the walls of the alveolar process on the other, being stretched across the intervening space in various directions.

The periodental membrane is highly supplied with nerves which enter through the walls of the alveolus and by way of the gums below the alveolus.

DEVELOPMENT OF THE TEETH.

The development of the teeth begins from the sixth to the seventh week of fœtal life. Prior to this time there is a thick projecting ridge of epithelium cells, known as the dental ridge, which extends along the whole length of the jaw. At this time a depression is formed; the dental groove in the mucous membrane of the gum. This is also filled with layers of epithelium which form follicles or sacs. They correspond in number to the temporary dentition, there being one for each temporary tooth. The dental groove gradually deepens throughout its whole length, and later is filled with epithelium cells, which form the enamel organ. Each follicle or sac cor-

responds to a tooth and is divided from those adjoining by prolongations of connective tissues, covered by the periodental membrane which passes across the groove. This forms the tooth socket. From below in the lower jaw and from above in the upper jaw a papilla of connective tissue grows towards the follicle which later on becomes the dentine organ being covered by the enamel organ like a cap.

At about the fourteenth week of fœtal life a vascular tissue is developed about the enamel organ and dentine germ which becomes the dental sac. Several weeks later the papillæ undergo a change and assume the forms of the crowns of the teeth. Small membranous lid-like coverings are developed from the side of the follicle, corresponding in number and shape with the table surface of the teeth. The side of the follicles and the lid-like membrane close and form sacs. Just previous to the closing of the sacs of the milk teeth, a depression is noticed behind and inside of each follicle. These are the cavities of reserve which eventually form follicles for the development of the permanent teeth which replace the temporary. The papilla enlarges and is converted into the pulp which resembles the crown of the tooth. The process of calcification now begins; a thin layer of dentine is developed from the covering membrane on the outer part of the pulp, layer after layer being deposited from the substance of

the pulp, which gradually decreases in size as the dentine increases. At the same time the enamel is formed from the enamel organ, it being deposited in crystals, the cement is produced from calcification of that portion of the periodental membrane lying next the tooth. As calcification advances, the tooth presses its way through the gums, which become absorbed. At the same time the divisions between the teeth become ossified, so that each tooth is wholly surrounded by bony structures, except the crown which is gradually pushed up by the lengthening of the roots. As the tooth grows the dental sac elongates gradually diminishing in size owing to the formation of dentine on its outer surface, until only a small cavity is left in the center of the root in which rests the dental pulp.

CHAPTER III.

TEMPORARY DENTITION OF THE HORSE, OX, DOG AND PIG.

The temporary (sometimes called milk or deciduous) teeth of the foal are twenty-four in number, twelve incisors or nippers and twelve molars or grinders, six above and six below of each kind. They present a dental formula, thus:

Incisors, $\frac{3}{3}$—$\frac{3}{3}$; molars, $\frac{3}{3}$—$\frac{3}{3}$=24.

The temporary molars are up at or a few days after birth; but the incisors make their appearance at different periods.

The incisors are divided into central, those nearest the mesian line; lateral or dividers, those on either side of the central; and corners, those on the outside. They are sometimes known as the first, second and third pair.

At birth the foal usually has no teeth, but a membrane-like covering for the incisors. The molars appear in two or three days. The incisors are cut in pairs, two above and two below at a time. The first pair protrude at from birth to eight days, usually about the fifth. The second pair at from four to six weeks. It usually takes about two months for the

first and second pairs to attain their growth. The third pair is cut at from six to nine or ten months, the time varying much more than for the other teeth. It also takes longer for this pair to develop, usually about three months.

The cutting of these teeth, unlike those of children, do not seem to give any trouble whatever to the animal. The gums do not swell or tumefy, but retain their natural appearance.

During this time the foal feeds well, seemingly suffering no inconvenience during mastication.

The milk teeth are smaller and whiter, with a better marked neck than the permanent teeth. (Fig. 6—5).

The outside covering, the encircling enamel, is very thin and nearly transparent. This milky whiteness *" is due to the absence of crusta petrosa; their crown is finely striated and not cannular on the anterior surface. The external infundibulum is shallow; they are not constantly pushed out from their cavities, their growth ceasing when they begin to be used."

The central pair of incisors is the longest and the corner one the smallest. The average size of the incisor teeth is about an inch and a quarter in length, one half to three-fourths inches wide, and about three-eighths of an inch in diameter; convex on their

*Chauveau.

external surface and slightly concave on their internal surface, with a groove running the whole length of the tooth. As the teeth become older they change in color, and assume more of a yellowish tint. The growth of the jaw forces them apart, so that each tooth stands by itself. These teeth, unlike the permanent ones, are seldom covered with a thick coat of tartar.

The molars are about an inch and a quarter in length and nearly an inch in diameter. The short—transverse—diameter of the upper molars is about three-quarters of an inch, and of the lower molars much less. The temporary molars are much smaller than the corresponding permanent ones.

The incisor teeth are shed in the order in which they are cut. The first pair is replaced by permanent teeth at two and a half to three years, and are up and in wear before the next pair are ready for shedding, thus leaving two pairs of sound teeth in wear for masticating food, during the whole process of shedding. The second pair are shed at three and one-half to four years, and the third at four and one-half to five years. At five years of age the permanent teeth are all up and in wear. All incisor teeth, both temporary and permanent, present their anterior side first; after they are in wear for a short time, it is reduced to a level with the inner surface.

The fourth molar makes its appearance at the

tenth to the twelfth month and is permanent. At two to two and a half years, the fifth molar is cut, and the first and second temporary molars replaced by permanent ones. At three and one half-years the third temporary molar is replaced by a permanent one, and at four and one-half to five years the sixth —permanent—is cut. At five the molars, as well as the incisors, are up and in wear and the horse is then said to have a "full mouth."

The temporary canine teeth are rarely ever noticed by the casual observer, they being very rudimentary, and thus far have received but very little consideration from veterinarians. This is probably due to the fact that they produce no serious results, and are so small that they are rarely ever seen.

*"Some veterinarians, and among them Forthomme and Rigot, have witnessed instances in which they were replaced; but the very rare exceptions cannot make us look upon these teeth as liable to be renewed. We must not, however, confound with these exceptional cases, the shedding of a small spicula or joint, which, in the majority of horses, precedes the eruption of the real tusks."

†"The small deciduous canine is cut about the sixth month, at about the time the third or corner incisors are cut. The lower tusk, owing to its diminutive size, and its being so close to the incisor, is shed

* Chauveau. † Prof. Owen.

almost as soon as the crown of the contiguous incisor is in full place, being carried out by the same movement." The deciduous canine of the upper jaw is shed the second year.

They are small and occupy the position that is eventually taken by the permanent canines. They are very small as compared with the other teeth, being from one-fourth to three-eighths of an inch in length and from one-sixteenth to one-eighth of an inch in thickness. I have invariably found them present in both colts and fillies, when preparing heads for anatomical specimens, provided the animals from which the heads were taken did not exceed six weeks of age. Up to that time they are thoroughly imbedded in the bones. The shedding of the teeth usually takes place in the spring and early summer. Occasionally we find colts that shed their temporary teeth in the fall and winter; but such instances are comparatively few.

TEMPORARY DENTITION IN THE OX.

The temporary teeth of the calf are twenty in number; eight incisors all below, and twelve molars, six above and six below. They present a dental formula, thus:

Incisors, $\frac{0}{4}$—$\frac{0}{4}$; Molars, $\frac{3}{3}$—$\frac{3}{3}$=20.

The molars are all up before, or a few days after birth; but the temporary incisors make their appearance at different periods.

The temporary incisor teeth of the calf are all situated in the lower jaw, and are eight in number. They differ from those of the horse in being turned more outwards. They are chisel shaped, convex on the external surface, and concave on the internal surface. The neck is small and much better marked than in the horse.

These teeth, unlike those of the horse, possess a certain amount of mobility, thus preventing injury to the cartilaginous pad above; they are not fixed in the alveoli. This condition is sometimes mistaken for disease and the poor animal has to suffer an operation, which varies according to the fancy of the operator. Some empirics have been known to scarify, and even burn the gums, in the vain hope "that they would heal and the teeth become solid in their sockets."

The incisors are divided into central, internal lateral (first intermediate), external lateral (second intermediate), and corner. *"The two temporary central incisors are always separated by a marked interval, depending upon the thickness of the fibro cartilage in the maxillary symphysis during youth."

The roots of the temporary teeth become absorbed by the permanent, as in the horse.

The anterior portion of the upper jaw is covered by a thick cartilaginous pad, continuous with the mucous membrane of the hard palate.

*Chauveau.

Rare instances occur where one or two incisor teeth are developed in the upper jaw; but they are so seldom noticed that a farther consideration than a mere mention is not deemed necessary.

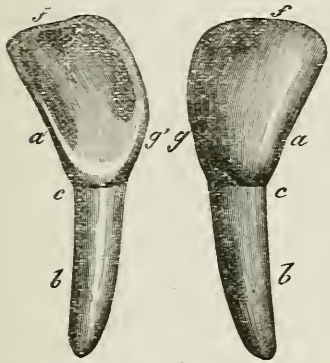

FIG. 8.

OX'S INCISOR TOOTH.

a, free portion, external face, outer border; *d*, *Ibid.* internal face, outer border; *b*, root; *c*, neck; *f*, anterior border; *g*, *g'*, inner border. *Chauveau.*

The central incisors and first intermediate (internal lateral), are up before or some days after birth; the second intermediate (external lateral), at fourteen days, and the corner by the twenty-first day.

The milk teeth of the calf are also much smaller and whiter, and as the calf grows, the spaces between them widen until they are finally shed.

The incisor teeth are shed in the order in which they are first cut. The central pair are replaced by permanent ones at one and one-half years, and are up and in wear at from one year and ten months to two years. The first intermediates are replaced by permanent ones at two and one-half years, and are up and in wear at three years; the second intermediates at three years and three months, and are up and

in wear at four years. The corner incisors are replaced by permanent ones at three years and nine months, and are up and in wear at four years.

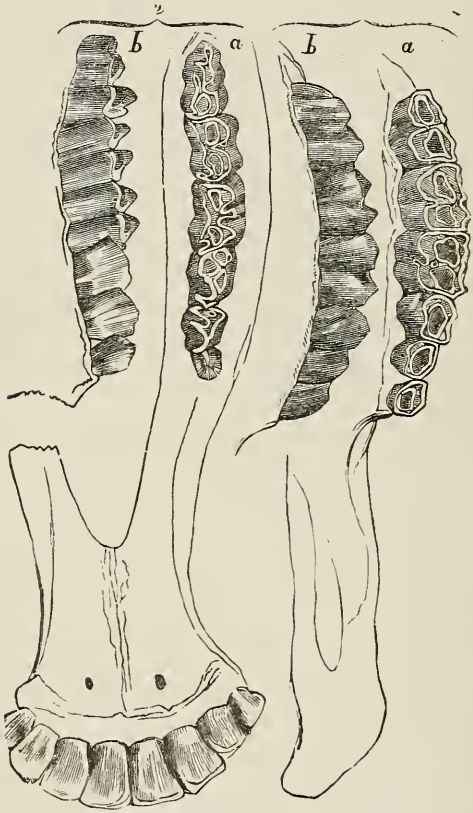

FIG. 9.

THE TEETH OF THE OX.

1, upper jaw with *a*, the friction surface and *b*, the external surface; 2, lower jaw with *a*, the dental tables, and *b*, the external surface. *Chauveau.*

The first molar is replaced by a permanent one at one and one-half to two years; the second molar at two and one-half to three years; and the third at three and one-half years. The fourth molar is cut as a permanent one at three to nine months. The fifth molar is cut as a permanent one at two to two and one-half years. The sixth molar at from three and one-half to four and one-half years.

The central pair of incisors are the widest and largest; they gradually diminish in both length and width toward the corners, which are the smallest.

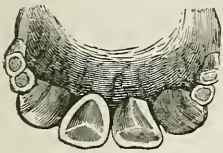

FIG. 10.

INCISOR TEETH OF A SHEEP TWO YEARS OLD.

The second intermediates and corner incisors have not yet been replaced.* *Chauveau.*

The temporary dentition of the sheep and goat is similar to that of the ox; they present the same dental formula, but differ in that the incisors present their free ends (table surface), to the cartilaginous pad above, while in the ox the posterior side of the tooth presses against the pad.

TEMPORARY DENTITION OF THE DOG.

The temporary teeth of the dog are thirty in number; twelve incisors, four canine, and

*It is almost impossible to give a correct dental formulæ of cattle owing to the various modes of treatment to which they are subjected. Some are so fed and housed that they mature early, while others do not get their growth until a much later period. The tendency to early maturity which is so highly developed in the beef producing breeds, is accompanied with a change in the period of dentition.

fourteen molars. They present a dental formula, thus:

Incisors, $\frac{3}{3}$—$\frac{3}{3}$; Canine, $\frac{1}{1}$—$\frac{1}{1}$; Molars, $\frac{3}{4}$—$\frac{3}{4}$.

The incisors, six in each jaw, are divided as in the horse, into central, lateral and corner incisors. They differ from those of the horse in that the central are the smallest and the corner the largest. The incisors of the upper jaw are larger than the corresponding teeth of the lower jaw.

*"The fangs, or canine teeth, two in each jaw are very strong, elongated organs, conical in form, curved backwards and outwards, and placed immediately after the incisors. The upper fangs are the thickest, and have a small space between them and the corner incisors, in which the inferior canines are lodged. These teeth are deciduous, like the incisors, and distinguished from the replacing ones by their being thinner and more elongated."

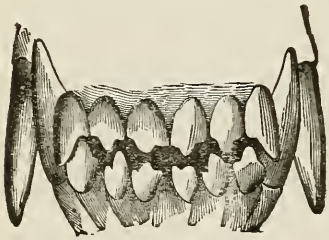

FIG. 11.

Anterior view of the canine and incisor teeth of a year-old dog.

The temporary molars are fourteen in number, six above and eight below. They vary in size, the first being the smallest and the last the largest. They each have a sharp projecting point

*Chauveau.

or lobe, which fits in the notch between the lobes of the opposite side. The temporary incisors and canines all make their appearance at from two to six weeks.

There are four temporary molars on each side in the lower jaw, and three on each side in the upper jaw. They are cut at about the same time that the incisors and canines make their appearance. The first temporary molar is the smallest and they gradually increase in size as they proceed backwards.

The replacement of the temporary or deciduous molars takes place in a manner similar to that of the horse. The first temporary molars are replaced by permanent ones at five to six months; the second and third at about six months, and the fourth (lower) a few days later.

The fourth upper molars, and the fifth lower are cut as permanent teeth at four to five months; the fifth upper and the sixth lower as permanent at five to six months; and the sixth upper and seventh lower, as permanent, at five and one-half to six and one-half months. The seventh molar (situated in the lower jaw), is sometimes cut much later and occasionally absent altogether.

DENTITION OF THE PIG.

Occasion seldom demands that an operation be performed on the teeth of the pig. Hence, I propose merely to make an allusion to the form of denti-

tion in that animal and will not again take up the subject.

The pig has forty-four teeth which are divided into twelve incisors, four canines, and twenty-eight molars.

FIG. 12.
Upper teeth of the pig, table surface. *Chauveau.*

The incisors, six in each jaw, exhibit very remarkable differences. The pincers (central) and the intermediate (lateral) of the upper jaw, offer by their form and the cavity they show on their table, some analogy to those of the horse. In the lower jaw these teeth are straight directed forward, and bear some resemblance to the incisors of rodents. The corner incisors of both jaws are isolated between the intermediate (lateral) and canine teeth, and are not nearly so large as the other incisors.

The tusks are very well developed, particularly in the male, and cross each other during the life of the animal. The canines are, as it were, self-sharpeners. In opening and closing the jaws, they glide against one another,

and wear their ends to a sharp point, thus making very dangerous weapons of them. Should the animal be inclined to make a detrimental use of them, they may easily be cut off with the tooth shears,

FIG. 13.

Lower teeth of the pig, table surface. *Chauveau.*

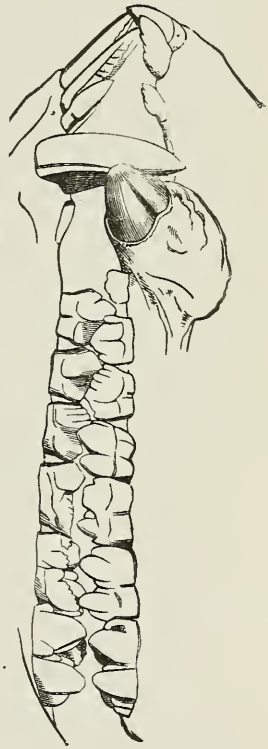

FIG. 14.

Lateral view of the jaws of the pig. *Chauveau.*

without injury to the animal. It makes the male more docile to have them removed.

The molars are seven in each row, and increase in size from the first to the last. The first four of each row are temporary and are replaced by permanent teeth. The temporary corner incisor teeth of the pig are up before, or some days after birth, and are replaced by permanent teeth at five to six weeks. The fourth molar makes its appearance as a temporary tooth at five to six months, and is also replaced by a permanent tooth at two years. The fifth appears as a permanent tooth at one year; the sixth at one and one-half to two years, and the seventh at three years. The temporary or milk teeth of the pig present a dental formula of:

Incisors $\frac{3}{3}$—$\frac{3}{3}$; Canine $\frac{1}{1}$—$\frac{1}{1}$; Molars $\frac{4}{4}$

and the permanent dentition a formula of.

Incisors $\frac{3}{3}$—$\frac{3}{3}$; Canine $\frac{1}{1}$—$\frac{1}{1}$; Molars $\frac{7}{7}$—$\frac{7}{7}$

CHAPTER IV.

ABSORPTION OF THE DECIDUOUS TEETH.*

"The processes of absorption of any tissue are in some ways similar to those observed in certain inflammatory affections. In inflammation of the hard tissues in other parts of the body there is noticed an action upon the bony materials by which they are slowly separated from the mass of hard tissue in their vicinity, and are at length either reduced to a form in which they may be taken up and removed by the natural organs of circulation, or they may be removed in part by absorption, and the remainder may be extruded from the place it occupied in the tissues, thus completing the removal of the substance from the body.

"All the hard tissues of the body are everywhere permeated by delicate filaments of connective tissue, which carry on the functions of nutrition in the part, and are the means of preserving its vitality. This is true in the teeth as well as in other forms of hard animal tissue, and may be traced into the finer canals of the dentine and has been thought to penetrate even the structure of the enamel.

*Blodgett.

The process of absorption of a temporary tooth commences at the apex of the root in cementum which has heretofore shown no indications of any tendency to disease. The first recognizable step in the process of physiological removal of the primary teeth is found in a roughness of the cementum, a corrugation of the exterior of the root, with the solution or at least the softening of the surface of the cementum thus affected. This diminution of the firmness of the dental textures is then followed by the entire removal of the tissue at the root of the tooth and a progressive advance of the process of absorption towards the mucous membrane, until there remains only the margins of the gum to afford attachment to the crown of the tooth, the radical portion having entirely disappeared from the jaw.

"The exciting cause of the normal absorption of the tissues of the milk tooth is the approach of the secondary or permanent tooth in the course of its development. The second tooth growing from its papilla in an upward direction towards the position it is to occupy in the alveolar process, comes into immediate proximity with the root of the deciduous tooth. The continued increase in the development of the secondary tooth is the cause of active phenomena at the apex of the root of the deciduous tooth, which resembles in many respects those of a moderate inflammation of the root. The result is a

gradual reduction in the volume of the root, which is in an exact relation to the advance of the crown of the permanent tooth, so that at the time when the deciduous tooth is ready to be extruded from the jaw, the crown of the permanent tooth which is to succeed it is often visible in the depression left after extraction of the remains of the milk tooth.

"The manner in which the absorption of the root of the milk tooth is accomplished has been the subject of careful study, and many theories have been advanced to explain this singular phenomenon. The most celebrated investigators in the domain of dental science have given the subject much attention. Czermak, Bodeker, Tomes and more recently Abbott have made valuable contributions to the solution of the question, which, however, cannot yet be said to be absolutely settled. All observers unite in describing the gradual excavation or corrugation of the hard textures of the root of the tooth, very similar to the appearances noticed in the absorption of portions of ivory, surgical cat-gut, silk, etc., when brought into relation with the textures of the living and healthy organism. The substance of these materials is invaded by numerous cavities, in which a softened and jelly-like content is found, and which penetrates further and further into the textures of the tissue. The advance of the process of softening is followed by continuous absorption of the dis-

integrated textures of the tooth, and in this way is brought about the removal of the entire radical portion of the dental structures. There is no attending suppuration in the process of absorption, and the entire course of the process is devoid of pain. There is often a certain amount of redness and swelling of the soft structures about the neck of the deciduous tooth during the process of absorption, but this may well be due, in part at least, to the irritation of the tissues about the part, caused by pressure upon the shortened and loosened deciduous tooth, and also to the natural tendency to vascularity accompanying any process of growth or development.

"The process of natural absorption of dentinal tissues bears no relation to caries of these textures. This event is one of natural removal of normal structures. Caries is the pathological degeneration of the same structures, by means of disease, and is accompanied, if not caused by chemical action and is universally the seat of disorganization of the tissues of the tooth; it is also accompanied by the presence of bacterial organisms, and usually also by the putrefaction of the products of the disorganization of the tooth substance. Caries takes its rise at all times from without. Absorption progresses from the apex of the root. Absorption is accompanied by a new formation of medullary or myxomatous tissue which

invades the tooth structure and changes it into a material which can be taken up by the natural channels of the part. In caries the softening is caused by the chemical decomposition of the calcified tentures of the tooth-structure, and is accompanied by putrefaction and the presence of micro-organisms. In physiological absorption there is simple removal of the softened tissues without the occurrence of putrefaction or the presence of micro-organisms. Further researches in the domain of absorption of the hard tissues, and especially those of the deciduous teeth, are greatly needed, and it is to be hoped that from such studies the obscure points in relation to the physiological removal of the hard tissues may be elucidated."

CHAPTER V.

PERMANENT DENTITION IN THE HORSE AND OX. DENTITION TABLES OF HORSE AND OX.

The permanent teeth, both incisors and molars, are much larger and stronger than the temporary. The permanent incisors and first three molars absorb the roots of the temporary until there is but a small thin shell or cap remaining. This is gradually pushed out and finally displaced by feeding or biting on some hard substance, and drops out of the mouth.

In the horse the permanent teeth number forty; in the mare, thirty-six, the canine teeth being usually absent, although they may occasionally be found in them somewhat rudimentary.

Naturalists, for the purpose of classification, divide the back eeth into premolars, those which are shed; and molars, those which make their first appearance as permanent teeth and are never shed. This division, however, is not usually recognized by veterinary surgeons. They designate the whole number of back teeth as molars. We occasionally find supernumerary teeth (wolf teeth, Fig. 14), situated in front of the upper and lower molars—most

frequently the upper molars. I have in two instances seen these small supernumerary teeth situated in front of both upper and lower molars, and back of both upper and lower incisors, making in all for-

FIG. 14.
WOLF TEETH.
Showing differences in size and shape.

ty-eight teeth in those mouths, eight of which were rudimentary. This condition, however, I believe to be very rare. The permanent teeth of the horse present a dental formula of:

Incisors $\frac{3}{3}$—$\frac{3}{3}$; Canines $\frac{1}{1}$—$\frac{1}{1}$ Molars $\frac{6}{6}$; or
Incisors $\frac{3}{3}$—$\frac{3}{3}$; Canines $\frac{1}{1}$—$\frac{1}{1}$; Premolars $\frac{3}{3}$; Molars $\frac{3}{3}$.

An expert can readily distinguish between an upper and lower molar, also the side to which each belong. The lower molars have one groove on the external lateral surface, running perpendicular to the wearing surface, with the exception of the sixth, which has two grooves. The supero-internal surface contains uneven sharp projections with well-marked depressions. The supero-external surface is rounded and smooth.

The upper molars have two grooves or depressions on the outer surface instead of one, the anterior being the deeper of the two. Their inferior external edges are sharp and ragged. The infero-internal edge is somewhat rounded and only presents sharp points in exceptional cases. The upper teeth are much wider than the lower, and have much longer roots. The grinding surface of the lower molars is slightly concave, those of the upper slightly convex, although in most mouths a straight edge will touch all the teeth in a row if laid on their grinding surface.

The roots of the upper teeth all incline slightly backwards. In the lower jaw the roots of the anterior three molars point slightly forwards, and the roots of the posterior three point slightly backwards, leaving a small space between the third and fourth molar teeth until they thoroughly develop. In some instances this space exists throughout life, affording a place for foreign substances and food to become lodged.

The incisor teeth meet edge to edge, and at five to six years the bodies are nearly perpendicular to one another. As the horse grows older they assume more of a horizontal appearance (stand out), until, in very old animals they sometimes have their inside surface nearly intact; they, like the molars, are the largest in the upper jaw.

The permanent teeth are cut in pairs, two in either jaw, the upper teeth preceding the lower by some weeks, with the exception of the canine teeth, which first show below. It is the cutting of the permanent teeth that inconveniences the animal, and often symptoms are noticed in the horse similar to those which occur in children during their first or temporary dentition.

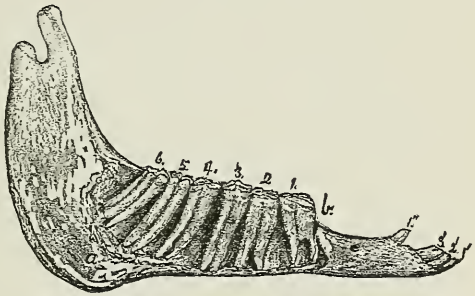

FIG. 15.

1' 2' 3', Incisors; 1," Canine; 1, 2, 3, 4, 5, 6, Molars. *a*, Position for trephining for 5 lower molar teeth.

The respective pairs of incisor teeth are usually cut at intervals at from ten to fourteen months; that is, the lateral incisors are cut ten to fourteen months later than the central, and the corner, ten to fourteen months later than the lateral. The same rule is not applicable to the molars, for they are all cut (twenty-four), during the same period the incisor teeth (twelve), are cut.

If we make the divisions, premolars (deciduous), and molars, then the rule will still hold good, for a pair in each group makes its appearance at the same time; but as has been stated, veterinarians designate all back teeth as molars, and it is the intention use that term only in this work.

In describing the periods at which permanent dentition takes place, diagrams will be used which represent one-half of the mouth as in figure 15.

The incisors being numbered 1, 2, 3—central, lateral and corner—and the molars in their order from before backwards 1, 2, 3, 4, 5, 6.

The dentition of the colt at ten months old is temporary and is represented thus:

Incisors.	Molars.
1, 2, 3.	1, 2, 3.

Permanent dentition is as follows: T, denoting temporary, and P, permanent teeth.

	Incisors.	Canine.	Molars.
	1, 2, 3.	1.	1, 2, 3, 4, 5, 6.
One year....	T T T		P T T P O O
Two years..	T T T		P P T P O P
Three years.	P T T		P P P P P O
Four years..	P P T	P	P P P P P P
Five years..	P P P	P	P P P P P P

At five years these teeth are all up and in wear; the colt then becoming a horse and the filly a mare.

The incisor teeth will average about two and a

quarter to two and one-half inches in length when they are fully developed. They shorten by being worn away on their table surfaces, and are much wider from side to side in a young animal, while in very old horses they are widest from before back. The upper teeth are the larger and usually have the outer edges of the corner incisors projecting, so that they do not wear evenly, leaving a point of more or less length, which gradually increases with age until the horse is from fifteen to sixteen years old. After this, owing to the gradual change in the position of the incisor teeth the outer edges of the corner teeth slowly come into wear again, and the size of the projection decreases until, in very old horses, it occasionally entirely disappears. The projection is very often removed by artificial means without bad results.

The molar teeth differ very materially with regard to the number of their roots. The first and sixth molars of both jaws each have three roots; the second, third, fourth and fifth upper molars have each four roots, while the corresponding lower molars have only two roots. They also differ in size; the first is the largest and shortest, the third the longest and the fifth has the smallest grinding surface.

In extracting teeth it is of importance that the operator should know the direction of each individ-

ual tooth while located in their alveolar cavities, and for that purpose I have inserted figure 15 and figure 32 which were taken from the jaws of a six-year-old horse of good size. The following figures represent the measurements of the teeth of the same head: Length of lower rows, $6\frac{6}{8}$ inches; upper rows, $7\frac{1}{8}$; distance between sixth lower, $2\frac{5}{8}$; between sixth upper, $3\frac{3}{16}$; distance between first lower, $1\frac{9}{16}$; between first upper $2\frac{1}{16}$; distance between the fourth lower, 2; between the fourth upper, $2\frac{5}{8}$. Length of first lower tooth, $2\frac{3}{4}$; first upper, $2\frac{7}{9}$; sixth lower, 3; sixth upper, $3\frac{3}{4}$; third lower, $4\frac{1}{16}$; third upper, $3\frac{15}{16}$. The third tooth in each jaw was the longest. The pulp cavity in the teeth was still present, and extended about an inch up into the tooth, and was $\frac{3}{16}$ of an inch in diameter. Lower tusk from first molar, $3\frac{5}{8}$; from third incisor, $\frac{11}{16}$. Upper tusk from first molar, $2\frac{15}{16}$; from third incisor, $1\frac{5}{8}$. Space between the lower corner incisor, from center to center, $2\frac{1}{4}$; between the upper, $2\frac{5}{16}$; between lower tusks, $2\frac{1}{16}$; between the upper, $2\frac{1}{4}$. The measurements will vary with the size of the animal.

Prof. Clark, in "Horses' Teeth" gives the following figures:—"Length of grinder rows, 7 inches. Space between the sixth grinders, upper rows, measuring from the inner surface, but not including the angles, 3 inches; center of rows, $2\frac{13}{16}$; first grinders, not including the space of the angles, $2\frac{1}{16}$. Lower

rows, between the sixth grinders, $2\frac{5}{8}$; center of rows, $1\frac{15}{16}$; first grinders, $1\frac{1}{2}$. Upper tusk from first grinder, $2\frac{7}{8}$; from third incisor, $1\frac{1}{2}$; lower tusk from grinder, $3\frac{1}{2}$; from incisor, $\frac{5}{8}$. Space between the upper tusks, 2; between the lower, $1\frac{3}{4}$. Space between the upper corner incisors, measuring from center of teeth, 2; lower, $1\frac{15}{16}$; between the upper dividers, $1\frac{1}{2}$; lower, $1\frac{3}{8}$."

PERMANENT DENTITION OF THE OX.

The ox has thirty-two permanent teeth; eight incisors, all in the lower jaw, and twenty-four molars, twelve in each jaw. Cattle, like horses, experience more or less difficulty while the process of the second dentition is taking place, although in a more modified degree. This is owing, to a certain extent at least, to the absence of canine teeth, which are a source of great trouble to the horse.

The permanent teeth are much larger and stronger than the temporary ones. The incisors are wide and have a well marked neck; as age increases and the wearing continues they gradually get shorter and shorter, the space slowly widens, all diameters diminish, and by the time the ox is twelve or fourteen years old, there only remains a stub whose table surface is nearly or entirely round, and very short. This is gradually pushed up by the contraction of the gums, and, in very aged animals entirely disappears, so that they become toothless so

far as their incisor teeth are regarded. As the teeth become worn down, the gums come more and more into wear, and in a measure assume the function of the teeth. The ox will continue to thrive fairly well in the pasture or stable, providing the molars or grinders perform their proper function. The corner incisors are sometimes regarded as the canine teeth, which, through the process of evolution have gradually approached the incisors until they at last rest by their side and present all the different characteristics accorded the other incisor teeth.

There are very few cases where incisor teeth are developed in the upper jaws of cattle. Thus far but one recorded case has come under my observation, and that is related by M. Roche Lubin, who says:—"On the 14th of April, 1837, I was requested by M. Bonhome, who lives near Rhodez, to extract a tooth which was growing in the middle of the palate of his young bull. The novelty of the thing made me hasten to comply with his request. The animal being secured, I removed the tooth in the usual way. A very considerable hemorrhage followed its extraction, which was performed with some difficulty on account of the tooth being firmly implanted in the palatine arch. It was situated at the middle of the median line, and was precisely of the same character as that of the usual incisor tooth of the ox."

The molar teeth of the ox, like those of the horse,

are twenty-four in number and are situated twelve in each jaw. When viewed individually they present marked differences. The first molar tooth in the lower jaw is small, and, with the exception that it has two roots, very much resembles a large remnant, or wolf tooth of a horse. The teeth gradually increase in size from the first to the sixth, which is about three and one-half times wider from before back than the first, and the wearing surface five times wider from side to side. The table surface of the lower molars is concave, the concavity amounting to one-half inch at its center. The teeth of the upper jaw are more even in size; the first being three-fourths of an inch in width from before back, and one-half inch from side to side, while the sixth is one and one-fourth inches from before back, and three-fourths inches from side to side. Their table surfaces present a convexity which fills up the concavity of the lower jaw when the mouth is closed.

Their wearing surface is constructed on the same principle as that of the horse's molars, except that the eminences and depressions are more acute. There is no special rule that is applicable to all the teeth, by which the upper molars of the ox can be distinguished from the lower; however, a careful study of each tooth will readily enable one to tell to which jaw and alveolar cavity it belongs. The roots of all the molar teeth point slightly backwards, and it is

owing to this fact that they are more easily extracted than the teeth of the horse. The lower molars each have two roots, while the upper have three roots.

The following measurements were taken from the teeth of a fair sized pure bred Holstein cow at five years of age. Length of lower rows, $5\frac{1}{4}$ inches; upper rows, $5\frac{3}{16}$; distance between sixth lower, $3\frac{9}{16}$; between sixth upper, $3\frac{1}{4}$; distance between first lower, $3\frac{1}{8}$; between first upper, 3; between third lower, $3\frac{9}{16}$; between third upper, $3\frac{11}{16}$ inches. The incisor teeth gave the following measurements: Width of arch, $3\frac{1}{2}$ inches; depth of concave of arch, $\frac{7}{8}$; length of protruding portion beyond the gum of centrals, $\frac{7}{8}$; length of central incisor, $\frac{11}{16}$ inches; of first intermediate, $\frac{9}{16}$; of second intermediate, $\frac{8}{16}$; of corner $\frac{6}{16}$. Width of central incisors, $\frac{11}{16}$ inches; of first intermediate, $\frac{9}{16}$; of second intermediate, $\frac{8}{16}$; of corner, $\frac{8}{16}$; distance between the first lower molar and incisors, $4\frac{1}{4}$ inches.

The following formula represents the age at which the teeth are up and in wear. They make their first appearance at from six to nine months earlier.

	1,	2,	3,	4.	1,	2,	3,	4,	5,	6.
*First year	T	T	T	T	T	T	T	P	O	O
Second year	P	T	T	T	T	T	T	P	P	P
Third year	P	P	T	T	P	P	T	P	P	P
Fourth year	P	P	P	T	P	P	P	P	P	P
Fifth year	P	P	P	P	P	P	P	P	P	P

*These deductions were made from personal observation on the teeth of a pure bred Holstein cow.

CHAPTER VI.

DISEASES DUE TO DENTITION—SYMPTOMS AND TREATMENT.

The temporary dentition of the horse, unlike that of children, produces no serious results. The temporary teeth are cut and developed without any apparent change in the animal system; the foal growing and thriving during the process.

It is quite different with the permanent dentition. The animal often exhibits the most distressing symptoms, losing flesh and often assuming a very dejected appearance which extends over a variable period.

The canine and sixth molar teeth are the source of the greatest difficulty. When the canine teeth are about to be cut the gums become swollen, tender and painful to the touch. In aggravated cases the animal refuses all solid food until pressed by hunger, when he will pick it up and handle it very carefully, endeavoring to place it as far away from the inflamed part as possible. In some instances he will chew the food for a short time and then let it fall out in the manger again. This condition has been met with on several occasions, and at first, I must say, it gave me some trouble to arrive at a correct diagnosis, little

suspecting that the trouble was to be found in the region of the canine teeth. A crucial incision with the scalpel over the point of and down upon the tooth is in most cases sufficient to cause the immediate subsidence of the symptoms, after which the horse will commence eating, and rapidly regain his natural condition.

Cases have come under my notice where the tumefaction in the lower jaw seemed to involve the incisor teeth, probably due to the close proximity of the canine teeth in that jaw. The whole anterior part of the jaw would become swollen and tumefied, the lower lip hang pendulous, and the mouth kept partially open, apparently for the purpose of relieving the pressure and admitting the cool air to the parts. Febrile symptoms are present at times, with a considerable rise of temperature, showing more or less constitutional disturbance; the febrile symptoms however, are usually only local and confined to the parts affected. These symptoms soon subsided after the canine teeth of that jaw had been cut down upon.

Professor Percival says, (Hippopathology, Vol. II, Part II, p. 226):

"There was a time when, I must confess, I treated the subject of dentition so lightly as to think that horses never suffered or became disordered from such a cause. Experience, however, has altered my opinion. I can now in practice frequently discover young

horses with disorder or febrile irritation upon them, the production or continuation of which I hesitate not to ascribe to teething, and I find these views are borne out by the relief obtained by the increased attention I am in the habit of giving to this assumed cause in my treatment. In illustration of this, I will here relate a case which occurred to me many years ago; the very one, in fact, which proved the occasion of my looking afterwards more closely into dentition.

I was requested to give my opinion concerning a horse, then in his fifth year, who had fed so sparingly for the last fortnight and so rapidly declined in condition in consequence, that his owner, a veterinary surgeon, was of opinion that the difficulty or inability manifested in mastication, and the consequent *cud ding* arose from preternatural *bluntness* of the sur faces of the molar teeth, which were in consequence filed, but without beneficial result. It was after this that I saw the horse, and I confess, I was at my first examination quite as much at a loss to offer any satisfactory interpretation as others had been. While meditating however, after my inspection, on the apparently extraordinary nature of the case it struck me that I had not seen any tusks.

I went back into the stable and discovered two little tumors, red and hard, in the situation of the in ferior tusks, which, when pressed gave the animal insufferable pain. I instantly took out my pocket

knife and made crucial incisions through them both, down to the coming teeth, from which moment the horse recovered his appetite and by degrees his wonted condition."

He further says:—

"The above case might likewise be quoted in illustration of another fact connected with this subject, which is that the cutting of the tusks—which may be likened to the eye teeth of children—costs the constitution more derangement than the cutting of all the other teeth together; on which account, no doubt, it is that the period from the fourth to the fifth year proves so critical with the domiciled horse. Any disease, pulmonary in particular, setting in at this interval is doubly dangerous, from its being augmented or kept up by the existing irritation of teething; in fact, teething is one auxiliary cause of the known fatality among horses at this period of their lifetime."

The effects of permanent dentition upon the constitution of the animal are many, and often of a severe character. In fact so much so that the animal will become very much depleted and will be unable to withstand many of the surrounding conditions which are productive of disease. Among such diseases may be noted catarrhal disorders, cough, swelling of the glands, irritation of the eyes, eruptions of the skin, derangement of the bowels, (constipation and diarrhœa), urinary disturbance, loss of appetite,

(as well as difficulty in mastication), pharyngitis and laryngitis (sore throat), and nervousness.

These diseases do not necessarily exist in all horses, any more than do their analogues in the human subject. Some animals are very susceptible to any change in the system, and they are the ones that become most often affected. As a general rule, well bred animals are the most susceptible to diseases of any kind.

The general symptoms which direct our attention to diseases of the mouth, whether in young or old horses, are discharges of saliva from the mouth with continual slobbering; cudding of the food; difficulty of mastication or deglutition or of both; stench of buccal secretion, perhaps of breath as well; more or less discharge from the eye; more or less nervousness; exhibition of pain while drinking; constant motion of the head while at work; failing appetite, and consequently a falling off in condition.

When the above symptoms are present, one should not fail to make a careful examination of the mouth. In fact, if I am called to treat a horse that is in his fifth year, I always look well to his teeth, and in a good many instances I have been able to diagnose the case without any further examination. Mistakes are oftener made in diagnosis by ignoring the mouth, than by placing undue weight upon a proper examination of that cavity.

The cutting of the sixth molar is often preceded by a troublesome cough. This cough is loud, sonorous, prolonged and paroxysmal, the animal coughing twenty, thirty, or even forty times without stopping. It is a throat cough originating in laryngeal irritation, which the animal tries to rid itself of by coughing. The larynx becomes swollen and very sore in some instances from the transmission of the irritation from the seat of the tooth to that organ.

Very often the horse is subject to various modes of treatment calculated to relieve the cough, but without benefit. This is not due in all cases to inefficiency on the part of the veterinary surgeon in charge; but rather to carelessness in the examination. A case of this kind came under my notice where the horse had been subjected to treatment for ten weeks, previous to my seeing him. All the remedies calculated to relieve a distressing cough, had in turn been administered without any perceptible benefit to the animal. I examined the mouth and found the gums very much swollen and tumefied over the lower sixth molars; when pressed upon the horse evinced the most excruciating pain, and endeavored to tear away. I made several bold incisions over each tooth cutting down against them. The animal seemed much relieved, and in a few days the cough entirely disappeared. This is only one of many cases of a similar nature that have fallen under my observation.

The cutting of the upper sixth molar frequently causes slight catarrhal disorders. There will be a thin, clear, watery discharge from one or both nostrils, usually the latter, which will continue as long as the irritation exists.

It is at this age that "*wolf teeth are so destructive to the eyes.*" It is a well known fact that small supernumerary teeth (wolf teeth so called), exist in most animals at this age unless previously extracted. Their presence however, has nothing to do with disease of the eyes. The discharge from the eyes is due to the eruption of the last molar, and usually subsides when that tooth is once through the gums.

Opthalmia, both periodic (moon blindness) and simple may result from teething; but in such cases we would suspect an hereditary tendency or predisposition to those diseases, which only want a sufficient stimulus to cause them to break out, when they will make their appearance.

The removal of supernumerary teeth (wolf teeth), lancing the gums or withdrawing any teeth, acts as a counter irritant, and may possibly be followed by the remission of some of the opthalmic symptoms. An incision or a blister below the eye often will produce the same result, so also will bleeding from the angular vein. Wolf teeth can never be looked upon as the source of serious disease of the eyes. If their removal is desired, it should be accomplished

by use of the elevator, or wolf teeth forceps, Fig. 16–17. Punching them out merely breaks them off, and at most is a cruel practice, not worthy of a moment's consideration. Some horses are very nervous at this time, throwing up the head every few moments while in harness. The nervousness usually passes away as soon as the teeth become fully developed.

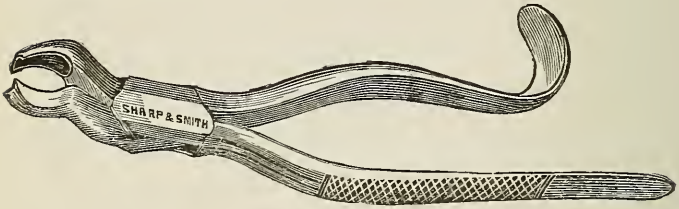

FIG. 16.



FIG. 17.
CURVED AND STRAIGHT WOLF TOOTH FORCEPS.

In regard to dentition fever Hutrel D'Arboval says:

"A sort of local fever originates in the alveolar cavities, running high or low according to the resistance the teeth encounter from the hardness of the jaws, or their own disproportionate size and solidity. The gums become stretched from the pressure of the teeth against them; they dilate, sometimes split; at the same time they are red, painful, and hot, even to

a sense of burning. Internally, the roots of the teeth from shooting downwards compress the dental nerves, and painfully drag the periosteal linings of the alveolar cavities. These combined causes will sufficiently account for the local irritation and suffering accompanying teething, and enable us to explain many morbid phenomena we find appearing in horses about this time from various circumstances, the most critical period of their lives."

Horses from four to five years old are more subject to this species of dental irritation than those younger, and it is well known among horsemen that they will stand more fatigue at a younger age than they will at this. It is a common expression that "I had rather work a three than a four year old horse; they will stand more."

If the temporary teeth seem to hinder the eruption of their successors, they are to be removed. Care, however, should be exercised in removing temporary teeth. It should be evident, beyond doubt, that they are causing trouble and are retarding the growth of the permanent teeth that succeed them. It is said that the temporary tooth, in becoming absorbed, furnished cement for the permanent teeth. Clarke says, ("Horses' Teeth," p. 48):

"It naturally follows that much of the cement surrounding the crowns of the permanent teeth, is derived from them (temporary teeth), thus lessening

the drain on the permanent tooth pulps, which are all the better able to supply cement for the roots of the permanent teeth. The scarcity of cement on the crowns of milk teeth is probably owing to the fact that they had no cement to absorb. The evil of extracting healthy milk teeth is obvious." The elevator is a very handy instrument for removing the caps or deciduous molars when they once become loosened. Just insert the bent portion between the cap and permanent tooth and by giving it a sudden twist the separation is easily effected.

The practice of extracting incisor teeth is sometimes resorted to by unscrupulous dealers who wish to make their horses appear older than they really are. After the teeth have been extracted the mouth has somewhat the appearance of having shed those teeth in the natural way. This deception when practiced, is easily detected by any one who is acquainted with the mouth in its natural condition. Unless the temporary tooth has been removed by artificial means, the permanent will make its appearance before it (the temporary) is shed.

Cattle frequently suffer from the cutting of the teeth, as well as the horse. There will be loss of appetite, redness and heat of the mouth, the gums will become swollen, tumefied and very painful to the touch; the head hangs down and there will be a discharge from the eyes and nose, with alternate con-

stipation and diarrhœa. The cough is not so severe as in the horse, but such as would lead the casual observer to think the animal was suffering from a slight cold or bronchitis. The animal will often stand away from the rest and appear more or less dejected.

Speaking of diseases occurring during dentition, Professor Williams says: "In young cattle, ranging from two years old and upwards, the cutting of the permanent molar teeth is occasionally a matter of some difficulty, owing to the unshed crowns of the temporary ones becoming entangled in the new teeth, proving a source of irritation, and preventing the animal from feeding. In some parts of the country such animals are called 'rotten' from their emaciated condition, and perhaps from the odor emanating from the mouth, arising from the imprisoned and decomposing food."

"When an animal of this age is seen to stop feeding, to lose condition, or to drivel from the mouth, it is necessary that the mouth be duly examined, and, if the unshed teeth are the source of irritation, they ought to be at once removed. Many hundreds of young cattle have been sacrificed from this cause; when a proper examination has not been made, they have actually died in the midst of plenty."

Dogs and sheep frequently suffer from the same disorders and present similar symptoms, which when found to be present should receive prompt attention.

CHAPTER VII.

CARIES OF THE TEETH.

Forms, Causes, Symptoms, Results and Treatment.

Caries of the teeth of the domestic animals is of frequent occurrence and so rapid is its progress that the whole tooth or even adjacent teeth become involved before its existence is noticed. Occasional cases however, produce marked symptoms at the outset, even before the roughness which it produces can be detected by the most delicate touch. No part of the tooth is exempt from this disease. It may attack the external surface of the crown, neck or root, or it may begin in the center of the tooth around the pulp cavity and gradually extend outward. Yet there are places which are more liable to attack than others. The depressions on the grinding surfaces of the molars and the neck on the side opposite an adjoining tooth; the latter no doubt being due to an accumulation of food between the teeth.

The molars are the teeth usually affected, the incisors rarely, and the canines practically never suffer from this affection. In no instance has there been brought to my notice a case of carious canine

teeth in the living animal, although I have seen its effects on those teeth in one skeleton.

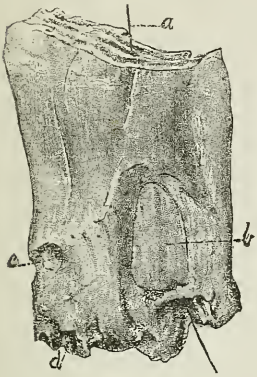

FIG. 18.
FIRST LOWER MOLAR SHOWING EFFECTS OF CARIES.
a. Wire passing through cavity of tooth. *b.* Removal of dentine, the result of caries. *c.* Inferior opening of *a.* Fig. 20. *d.* Caries of the fang.

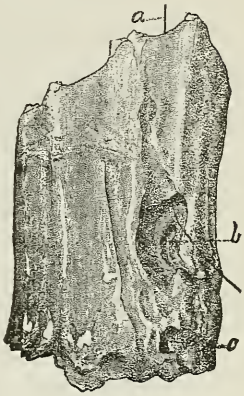

FIG. 19.
SAME TOOTH OPPOSITE SIDE.
a. Wire drawn through cavity extending to *b.* *c.* Continuation of same cavity.

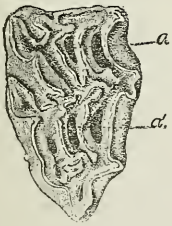

FIG. 20.
TABLE SURFACE OF TOOTH REPRESENTED IN FIGURES 18 AND 19.
a, *b*, Opening of cavities on table surface.

The attack and progress of caries are much modified by the constitution of the teeth. These may be defective either originally or accidentally. Original defectiveness extends to all the teeth of the same individual, due to a constitutional predisposition, whilst accidental defectiveness exists only as to some of the teeth in

the same mouth, and in many instances these only at particular points. Such conditions are peculiarly favorable for the attack of caries. When the whole crown of the tooth is imperfectly organized, the decay will progress with uniform rapidity under the influence of uniformly persistent agents till the whole is destroyed. But when it is only a portion of the tooth, the caries may after a time become retarded in its progress, and in some cases checked altogether.

By making an examination of the teeth of a large number of horses which were destroyed for dissection, the latter condition referred to was frequently found present. In some subjects teeth were found with a central depression on the table surface, which extended to a variable depth and to all appearances were perfectly free from any carious particles. In others small specks of decayed, earthy material were noticed on the sides of the cavities while the bottom of them was perfectly sound. Every gradation from a perfectly healthy to a completely diseased cavity has been noticed.

In examining the teeth of living animals I have often found the same condition present.

Among the many circumstances which modify the progress of this disease, are a change in the character of the agencies producing it, as well as an increase or diminution of the amount of such agen-

cies. The mutability of these agencies are almost infinite, being constantly modified by various external and internal causes ever present.

The progress of caries will also be governed somewhat by the age of the animal whose teeth it attacks, the nature of the food, as well as the constitution of the teeth themselves. The normal constituents of the teeth present almost an infinite variety of relative proportions, even in animals of the same age, and continually varying at different ages. As age progresses the teeth like the bones are constantly undergoing a change; the earthy elements increasing and the animal decreasing. This condition arises from defective organizing power or from a failure in the arrangement and combination of materials and is entirely dependent upon accidental causes.

The greater the nutritive supply of a tooth the less liability will there be to caries, hence diminished nutrition increases the liability of caries; in old animals and especially horses, the teeth receive but little nourishment, so that in them we oftener find decayed teeth than in young animals.

The decayed portion of the tooth varies in color according to the hardness of the teeth. In some it is black, in others brown, while in some it is nearly white, varying but little from the natural color of the tooth. There are no doubt other circumstances

which influence the color of the decayed part, but just what they are is not easy to determine.

The study and investigation of the phenomena attending caries of the teeth of domestic animals, is a difficult problem and one not easily solved. Professor Williams says: "Caries, dental gangrene or decay, is almost exclusively confined to the molar teeth, although I have seen the incisors in that condition.

*Caries of the molars may commence primarily with the fang, neck or crown of the tooth.

"Caries of the fang arises from inflammation of the pulp, and may be caused by a constitutional predisposition or external injury. Inflammation of the pulp does not always cause caries. I have seen several cases on record where the fangs were enlarged from a periodental deposit, with abcesses surrounding the fangs without caries. Caries commencing at the fang may be due to obliteration of the pulp cavity at an age when the vitality of the tooth depends upon the integrity of the pulp. I need scarcely remind the professional readers that the integrity of the teeth depends upon due supply both as to quantity and quality of nutritive materials. On the fangs of the recently cut tooth but little crusta-petrosa is met with, compared with that which exists in old teeth. As age advances the crusta increases and the tooth grows from the outside.

* Williams.

In proportion as the pulp diminishes, so is the supply of nutriment to the tooth lessened, until at length it is entirely cut off from the interior; and to provide for the vitality of the tooth under these circumstances, the crusta-petrosa increases in quantity on the fang and at the expense of the perfectly formed dentine lying in immediate contact with its inner surface. That is to say, this layer of dentine is converted into crusta-petrosa by the dental lacunæ undergoing dilatation and becoming identical with the hollow spaces or cells of the crusta. The tooth now draws its nourishment from the blood vessels of the socket, and thus it continues long after the obliteration of its pulp cavity, to serve all purposes as a part of the living organism. This is the natural condition of old teeth; but when the pulp cavity is obliterated at an early age by a too rapid formation of dentine, and consequent obliteration of the pulp, when the crusta is not yet sufficiently developed to supply nourishment to the whole tooth, caries must be the result.

Many cases of caries of the teeth that have come under my observation, have resulted from the above cause and very often the disease is confined to that part of the crusta-petrosa that dips with the enamel into the interior of the tooth, splitting up the tooth into several perpendicular fragments from crown to fang.

FIG. 20.
GENERAL CARIES OF A TOOTH.

Caries of the neck (cervix) of the tooth is seen in those horses whose teeth are wide apart, and is caused by the food remaining in the interspaces and by decomposition exciting inflammation in the periodental membrane.

Caries commencing at the crown or table, is due to a portion of the dentine losing its vitality, and the power of resisting the chemical action of the fluids of the mouth; a portion of the enamel of the crown may be fractured by the animal accidentally biting a piece of hard stone or metal contained in his food. Mere fracture of the enamel is not sufficient of itself to lead to caries of the teeth of the lower animals, foı it is a substance that is gradually worn off by the attrtion of the teeth continually going on during mastication; but the pressure which has been sufficiently great to cause fracture of the enamel, may at the same time have caused such an amount of injury to the subjacent dentine, that it dies and progressively becomes decomposed.

SYMPTOMS.—There will be quidding of the food, in some instances the animal will pick up the hay, chew it until it is formed into a bolus thoroughly

mixed with saliva, then let it fall into the manger. I saw one case where the manger and floor of a box stall was literally covered in the morning with boluses of partially masticated hay. It gave off a very offensive odor, which was due to decomposition of the saliva and food. Some animals will hold their head to one side, in order to keep the feed from getting between the diseased teeth, will chew naturally for a time, then quit suddenly, drop the feed, and perhaps rest the affected side of the head against the manger or side of the stall. A foul odor will also emanate from the mouth in many instances. If in the lower jaw there may be external swelling, with a fistulous opening after a time, opposite the diseased tooth; if in the upper jaw, there may be a discharge from one or both nostrils (from one side only if there are carious teeth on one side, and from both sides if there are carious teeth on both sides) with more or less bulging of the sinuses, which upon percussion will give a dull sound. Tapping the tooth gives intense pain in many instances. The mouth internally will be more or less swollen, red, hot, tender and painful, while a tumor of considerable size may be seen or felt with the hand in the region of the diseased tooth.

On making an examination of the tooth there will, in the majority of cases, be found a cavity of greater or less extent. The whole tooth may have decayed leaving only the roots. In others one side

may have decayed away, leaving the remainder of the tooth thin and sharp, which in some instances leads to laceration of the tongue, if the inside of the tooth remains, and laceration of the cheeks if the outside remains. In other cases the tooth may be only slightly roughened where there will be a tendency to the accumulation of tartar. There will be more or less accumulation of food in the cavity, which when removed will give off a very offensive and disagreeable odor, giving rise to the popular term, "rotten teeth."

EFFECTS OF CARIES.

The effects of caries vary, but chief among them, is death of the tooth and its subsequent removal. If caries of the teeth exists in a young animal exposure of the pulp first takes place and there occurs that peculiar and well known sensation, so dreaded by the human family, toothache. Inflammation and suppuration follow, by which a discharge is established from between the margin of the gum and tooth, or a fistulous opening is formed. If the carious tooth is an upper one, and the third, fourth, fifth or sixth, this fistula communicates with the sinus opposite, but if the first and second, it communicates directly with the nasal cavities, and if the tooth is located in the lower jaw the fistula usually opens on the lower margin of the inferior maxilla, opposite the root of the affected tooth.

Caries of the third upper molars is frequently the source of excessive pain, and is to be very much dreaded. It is more sensitive when diseased than any other tooth, from the fact that the maxillary branch of the fifth pair of nerves make their exit upon the face through a foramen, which is located directly over the root of this tooth. This fact must not be lost sight of in trephining for its removal; for, should this nerve be injured in any manner during the operation, the animal will suffer greatly and become unmanageable for further operation unless it be cast and secured.

The fourth, fifth and sixth molar teeth of the upper jaw are situated directly below the large maxillary sinus, from which they are separated by a thin plate of bone. They communicate with the sinus as easily as do the first and second with the nose; but lead to far different results.

When inflammation or caries is sufficient to destroy this thin plate of bone, the pus which is formed passes into the sinus, sometimes particles of food accompanying it. By its presence the mucous membrane of the sinus becomes irritated and will either slough or become thickened, developing large elevations of the nature of polypi; or they may form osseous tumors. Both forms by addition attain sufficient volume to fill the sinuses and cause a bulging of the facial bones. The pus all this time is very

abundant, the more liquid portion passing out through the openings connecting the sinuses with the nasal chambers, while the thicker portion remains in the cavity. It gradually undergoes a transformation becoming thick and greasy looking, with a very offensive odor.

Should the above condition be present in a young animal, before the facial bones have become firmly united or grown together, the pressure exerted by the enclosed pus may be sufficient to force them apart, destroy the skin, escape through the fissures and pass down over the face. This condition does not often occur, yet I have noticed it on several occasions.

November 2d, 1888, Mr. N. Boyles, of Richland, Mich., brought to the infirmary a bay gelding twelve years old, suffering from a distension with pus, of the frontal and maxillary sinuses. There was a copious discharge of fetid pus from both nostrils as well as from an external opening which had formed just below the eye. The molar and lachrymal bones had had their articular surfaces separated allowing free exit for the pus.

The sides of the face presented a very disgusting appearance not unlike that usually noticed in severe cases of poll-evil and fistulous withers.

The diseased bone was removed, exposing the frontal sinus; the fingers and bone cutting forceps

being used for that purpose. Both right and left maxillary sinuses were then trephined and thoroughly cleansed by turning the hose into them. After removing all the pus the sinuses were treated with injections of carbolized water containing a small amount of common salt. These dressings were repeated daily for six weeks, at which time the horse was sent home much improved. The improvement continued until complete recovery took place.

This horse had a carious tooth extracted the previous September and was at that time also suffering from a discharge from the nostrils. Had the sinuses at that time been trephined so as to allow the pus to escape, the latter trouble would undoubtedly have been avoided.

If there is a fetid discharge from the nostril, due to a carious tooth, it is always advisable to trephine the sinus at the lower border, and as nearly opposite the diseased tooth as possible. The sinus should then be cleansed and afterward dressed with carbolized water, one part of the acid to thirty or forty of soft water.

Dr. Sayre, a celebrated veterinary dentist of Chicago, and who has had much experience in operating on carious teeth says: "I always trephine if there is a fetid discharge from the nostrils, due to carious teeth producing ulceration of the sinuses,

even if I first extract the diseased teeth with the forceps."

Tumors may make their appearance on the gums or exostoses on the roots, as a result of decayed teeth. A diseased condition of the alveolar process is occasionally produced by dead or carious teeth, as also in extensive caries of the jaw bone. Inflammation of the mucous membrane of the mouth (sometimes giving rise to the condition termed Lampas), is an exceedingly common result of diseased teeth. This inflammation may become very extensive involving the whole membrane of the mouth, extending to the throat, where it causes an irritable condition giving rise to a more or less troublesome cough.

Just how far this inflammation may extend is difficult to say, for the mucous membrane of the mouth, nasal chambers, sinuses, pharynx, larynx, oesophagus and bronchial tubes are continuous, without any definite line of demarcation. It does not seem probable that a number of diseased teeth involving in their disease (especially in young animals), all the ramifications of the facial nerves, and the whole mucous membrane of the mouth, could remain for any considerable period without producing grave results.

Indigestion in the chronic and even acute forms is frequently associated with carious teeth and

is due to imperfect mastication of the food. A very offensive and disagreeable odor is also emitted from the mouth, especially if the carious condition is far advanced.

Young animals affected with carious teeth yield more readily to its effects and sooner become emaciated than older animals similarly affected.

FIG. 21.
EXTERNAL SURFACE OF PERMANENT CORNER INCISOR TOOTH.

Figure 21 represents caries of the right lower corner incisor of a gray mare six years old. The corresponding temporary tooth was not shed in the natural manner. It remained in position until the mare was past five years of age, and was then removed with the forceps, but not until partially displaced by the tooth represented in Fig. 21. After the removal of the temporary tooth, the gums about the wound began to tumefy, and became very tender to the touch, so much so that it materially interfered with mastication. As a result the animal fell away in flesh and presented a rather dejected appearance. About six months after the first operation the gums were lanced and the tooth illustrated extracted, affording marked relief, the gums in a short time assuming a natural condition. This tooth being a permanent one has never been replaced by another.

FIG. 22.
A LONGITUDINAL FISSURE THE RESULT OF CARIES.

Fig. 22 is a drawing made from a tooth which represents a very common form of caries. A fissure (*a*) in the crown extending from the interior to the posterior edge of the tooth, dividing it into nearly equal parts, extends down the side (*b*) to the root. This is a very common form of caries, and usually terminates in longitudinal fracture of the tooth from the crown to the root. The fracture is the result of food collecting in the wedge-like groove and forcing it apart. Feed will accumulate in the fissure often giving a round bulging appearance to the cheek, which subsides as soon as the accumulation is artificially removed. Should the round, bulging appearance be due to paralysis of the muscles of the cheek, it will remain more or less pendulous after the feed has been taken away.

The fourth molars are more liable to caries than any of the other teeth. This is due no doubt to the fact that they are the first permanent teeth to make their appearance, consequently they are less developed than those which appear later in life. Being the first permanent teeth erupted they are subjected

to all the irritating influences attendant upon the removal of the temporary, and the appearance and development of the permanent teeth. There also is usually a space of greater or less width between the third (temporary) and fourth molars, affording lodgment for foreign substances.

TREATMENT.

If the disease exists to any considerable extent it will be necessary to effect the removal of the affected

FIG. 25.

UNIVERSAL MOLAR FORCEPS.

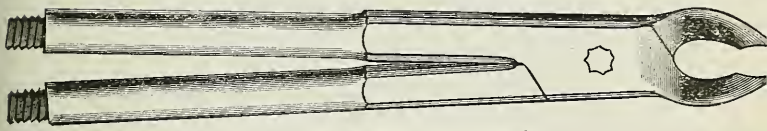

LARGE EXTRACTING FORCEPS.

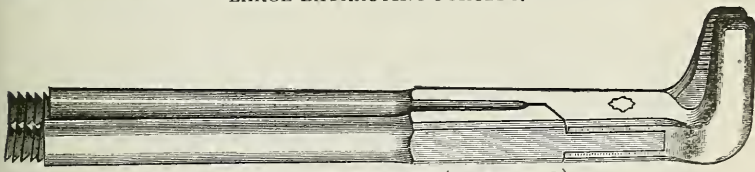

EXTRACTING FORCEPS (SIDE VIEW.)

teeth. If the disease is limited and the cavity small, the tooth may be filled, if located so that it is accessible. The incisors, canine and first three molars, can usually be reached with sufficient ease to effect a filling of the cavity. The subject of filling will be treated in a separate chapter.

CHAPTER VIII.

DENUDING OF THE TEETH.

This is an affectation which rarely attacks the teeth of the horse, though quite frequently affecting the teeth of the human family. It consists in a gradual wasting away of the enamel and underlying dentine on the external or labial surfaces of the incisor teeth, first attacking the central, then the lateral, and finally the corners. It begins nearest the table surface and forms a horizontal groove, which is very regular and smoothly constructed. After the enamel has been removed and the dentine exposed it rapidly continues its inroads upon that tissue. So rapid is this destruction of the dentine that it sometimes undermines the enamel to such an extent that it is broken off in shell-like pieces. The dentine assumes a brownish or grayish color with disintegration of its structure.

The process of this affection is exceedingly variable, sometimes so rapid that the dentine becomes exposed in a few months, while at other times its progress is very slow, requiring a number of months or years to remove the enamel. In all cases it is much more rapid in the horse than in the human

family, where the process of denudation is so slow that it often takes from ten to twenty years to accomplish the same result. It usually makes its appearance at the approximal corners on the labial surfaces of the central incisors. From here it gradually involves the whole labial surface of the tooth, after a time implicating the lateral incisors, which also at first become affected on their labial surfaces where they approximate the central pair of teeth. Unless

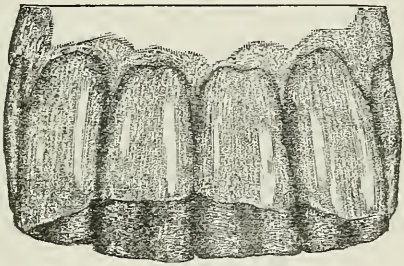

FIG. 23.

DENUDING OF THE CENTRAL AND LATERAL INCISORS.

the progress of the disease is checked or entirely impeded in its progress, it will gradually extend until it involves all the incisors of that jaw. As far as my observation and knowledge of this disease extends, I can not say that any other teeth than the upper incisors ever become affected. I see no reason however, why they should remain immured from an attack of this disease, unless its cause can be attributed to the acidity of the buccal secretions of the mouth.

On June 23, 1889, Mr. Shattuck, of Covert, Michi-

gan, offered a mare four years old for operation, presenting the following symptoms: The animal was much emaciated, had a parrot mouth, the upper jaw extending one inch beyond the lower jaw. Inferior incisors and molars sound and perfectly formed. The upper, central and lateral incisors were denuded on their labial surface, the whole of the enamel having been removed from the outer surface of the central pair. On examination the molars of the upper jaw were found to have assumed a like condition, there being but one of them that appeared sound (the first right upper). Their external surfaces were partially or wholly denuded, and in some instances the whole table surface was absent. The affected teeth were very sensitive when tapped with the forceps or mallet. The animal either refused all hard food or ate very sparingly.

My attention was next directed to a full brother of the mare, but two years older. A parrot mouth of about the same appearance was noticed. The incisor teeth of the upper jaw were dark, and showed signs of disintegration, and undoubtedly will soon become denuded. The lower incisors and all the molar teeth were of abnormal appearance.

On inquiring into the history of the dam of these horses, the owner informed me that the same condition was present, and that her teeth had been defective for some time.

This particular case seems to have been the result of hereditary transmission, and adds weight to the theory of original defectiveness as the cause of denuding of the teeth.

CAUSES.

I am unable to positively assign the cause or causes which produce denudation of the teeth. There are influences which do exist and might be brought to bear upon the teeth in such a manner as to bring about the condition described, but whether they *are* the true cause or not I am unable to say. Mechanical abrasion, friction of the lips, presence of acid in the saliva and original defectiveness of the enamel, as the seat of the disease, may all have more or less influence in the production of this pathological condition.

The latter (original defectiveness), I believe to be the true cause, though this is only a hypothesis which has not yet been definitely proven. It appears less objectionable than any of the other conditions enumerated. We do know that one or more teeth in a mouth may be defective without there being a corresponding defectiveness in the other teeth. Did the lower teeth as well as the upper become affected, the acid theory would seem very plausible. The buccal secretion contains an acid which in the back part of the mouth is mixed with saliva, which dilutes the acid to such a degree as to possibly render it

harmless to the molar teeth. It may be that the tongue and natural flow of saliva (owing to gravitation), over the lower incisor is sufficient to dilute the acid contained in the buccal secretion to such an extent as to render it inactive. The theory of imperfect organization, I am inclined to believe is the true cause of this affection. There is yet room for a more thorough investigation of this subject, though the number of cases coming under the notice of the veterinarian are very limited.

TREATMENT.

The only treatment which has thus far proved satisfactory is the thorough removal of all diseased tissue, and then filling the cavity. An amalgam composed of tin, silver and mercury answers all purposes. This effectually retards the progress of the disease for a time. In some cases all future difficulty is avoided in this manner. For instruction for filling teeth see Chapter XXI.

While preparing this chapter the following case was reported to me by A. C. Runyan, D. D. S., of Bangor, Michigan. The reported case is as follows: "I think the horse was about five years old, do not know what gender, owned by one of our liverymen here. It would not eat its food properly and in consequence was in very poor condition. As nearly as I can remember only the superior incisors were affected. The two centrals were the worst and appar-

ently had commenced at their approximal corners on the labial surface. One of them was completely denuded of enamel for one-fourth the distance up from the cutting edge and the others were nearly as bad leaving the dentine completely exposed. Consequently the teeth were very sensitive. There seemed to be a disintegration of the dentine at the point of union with the enamel. The carious dentine could be removed for nearly one-tenth of an inch under the enamel and was of a brownish or grayish color. The enamel of the affected teeth varied from the normal color at the gums to a white or chalky color where the disease was progressing to a light brown where it was crumbling away.

TREATMENT.

I removed all the carious dentine, cut back the enamel to where it seemed firm, made suitable undercuts and put in amalgam filling. The amalgam used was about equal parts of tin and silver melted together and run into an ingot and filed, and the filings mixed into a stiff paste with mercury.

I never have seen the horse since, but inquired about it once or twice. Its owner thought it could eat much better, but disposed of it in a few days after the operation, so I do not know how successful it may have proved."

CHAPTER IX.

EXOSTOSES, THEIR NATURE, CAUSE, SYMPTOMS AND TREATMENT.

An exostosis is a bony enlargement, and may exist on any part of the osseous framework. Ring bone, side bone bone spavin, and splints furnish us the best example as to its development. When confined to the teeth it attacks no other part of a fully formed tooth than the root. If it exists on the crown or free surface of a tooth it is developed with the tooth. As has been already noted the tooth consists of enamel, dentine and cementum, or crusta-petrosa. The latter alone only of these tissues contain sufficient vascularity for the development of these tumors.

The exostoses assume various sizes, shapes and positions. They usually commence near the extremity of the root, covering more or less the whole external surface. Others, however, surround the root at some distance from its extremity; and others develop on the sides forming a large tubercle like the one illustrated in Fig. 24.

Here we have one of those tubercles developed on each side, the deposition continuing until they at-

tained a great size. These tubercles have the color, density and structure of cementum. In some instances the color varies, assuming a yellow tinge. Such exostoses are usually harder than the lighter colored ones. In the human subject the deposition of osseous material is so extensive as to involve two or more teeth which become thoroughly united. This condition I have never observed in the domestic animals, with but a single exception; that being where the sixth and seventh lower right molars of a hog had become firmly united, resembling a single tooth.

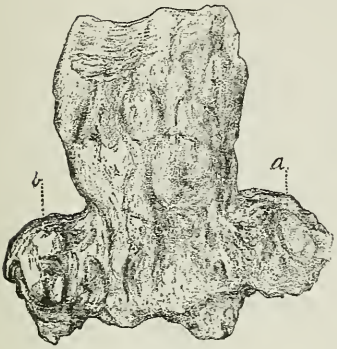

FIG. 24.

SECOND UPPER MOLAR.

Showing an exostosis *a*, *b*, on both sides, two-thirds natural size.

CAUSE.

Some attribute it to external injury; others to irritation of the periosteum surrounding the root. The tooth from which the above drawing was made is perfectly sound and does not show any signs of ever having been diseased. I am inclined to think it is due to a constitutional diathesis following the same

law as exostosis upon any other bony structures of the body.

TREATMENT.

The only treatment practicable is the extraction of the tooth, for when once established there is no remedy which will promote its absorption. In removing a tooth affected by exostosis great care must be exercised lest the alveolus, and even the bone itself, may become fractured. It is a good plan to trephine down onto the exostosis and remove a portion of the alveolus of sufficient size to allow the tooth to slip out without fracturing the jaw bone.

C. E. Sayre, D. V. S., of Chicago, Illinois, reported a very interesting case of an exostosis on the roots of a lower (third) molar tooth. The tooth had partially decayed and was a source of much trouble to the patient. Upon making an examination it was found that there had been complete separation of the tooth and dental periosteum allowing the tooth to become loose in its socket. It could be rotated very easily with the finger. He endeavored to remove it with the extracting forceps but did not succeed. Trephining was then resorted to, an opening being made directly over the roots of the tooth. On exposing them an exostosis was discovered completely encircling the tooth a short distance from the end of the root. This enlargement formed a complete circle around the tooth and very much

resembled a tooth that has had a buggy washer slipped over it, it being very nearly as prominent.

Fig. 24 represents an exostosis upon each side of the root, (*a*) and (*b*) representing the osseous enlargement. They show no signs of ever having been diseased. The specimen for the above drawing was presented by L. R. Brady, V. S., Manhattan, Kansas.

The following case was reported by Frank Allen, of the American Veterinary College:

* "On the 9th of February an aged bay gelding was brought to the American Veterinary College for dissecting purposes and on the 11th of February, when placed on table and about to be destroyed, his breath was found to have a very offensive odor and a muco-purulent discharge was observed from the left nostril; he had eaten all right from the time he was brought in, but no previous history could be obtained. The diagnosis of a decayed tooth was made and on post mortem the following lesions were observed:

The fourth upper molar on the left side was found loose and a very slight pull with the fingers brought it from the alveolus, which was extensively diseased and ulcerated; the mucous membrane and hard palate were thickened and discolored around the diseased tooth. On making a transverse section of the skull at the level of the fourth molar, there was noticed

*American Veterinary Review, Vol. XIII, Page 36.

between the superior and the turbinated bones in the middle meatus an irregularly shaped bony mass about two inches in circumference and weighing between two and three ounces; it was one and a half inches from the diseased molar. The pressure of this mass had caused necrosis and absorption of part of the superior turbinal and partial absorption of the nasal

FIG. 25.

THIRD LOWER RIGHT MOLAR SHOWING AN EXOSTOSIS WHICH INVOLVES TWO SIDES OF THE TOOTH.

bone above it, making a shallow depression not noticeable from without. The septum nasi on a level with this mass, had a circular hole the size of a fifty cent piece communicating with the right nostril and the whole of the mucous membrane was thickened and congested. The bony partition between the inferior maxillary sinus and the nostril was absorbed, clearly showing that at one time the growth had been at-

tached to the fang. The crown of the molar was perfectly normal. On making a section of the mass it appeared to be composed of material resembling crusta-petrosa.

The drawing in Fig. 25 was made from a tooth, taken from a horse, the property of Mr. William Charles, of Bangor, Michigan. The history of the case as given by Mr. Charles was as follows:

"For two years previous to the operation (Sept. 5th, '86), the horse had gradually declined in flesh, being unable to properly masticate his feed. After a time a foul and disagreeable odor emanated from the mouth, the gums on the right side of the lower jaw becoming red with gradual enlargement over the region of the third molar. As the disease progressed the difficulty in mastication increased, until the coarse feed had to be cut very fine. The grain consisted of corn, oats and wheat, which was ground as fine as possible. All kinds of feed were swallowed whole. By this mode of feeding the animal was kept in such condition that he could be worked.

On the above date I was requested to examine the horse and, if advisable, to operate. On making an examination of the mouth I found a large tumor over the region of the third lower right molar. It was of sufficient size to cause a bulging of the cheek that was noticeable at a distance. The tumor was partially denuded at its upper extremity. The third

as well as the second molar was loose in its socket, if it could be said to have one, and by moving the teeth I could feel a movement of the tumor corresponding to the movement of the teeth. The first molar of that jaw was also diseased, being slightly carious.

The third molar was first extracted with the forceps, the tooth coming comparatively easy; the second then fell out of the mouth of its own accord. The first was also extracted. The mouth was then thoroughly cleansed with carbolized water. When the animal was released he immediately began feeding on some grass which had been thrown into the manger for another horse. The mouth entirely healed up in eight weeks, the horse rapidly regaining his former condition. He was also able to eat whole grain and coarse feed which was thoroughly masticated, but requiring longer time than when his teeth were perfectly sound.

Two years later I was again called to operate upon the teeth of the same animal; they were all more or less diseased on that side of the head; were loose and when extracted were found to be covered with exostoses, which varied in size from a pin's head to a bean. This animal also suffered from a spavin. After carefully examining the above conditions I have come to the conclusion that in this case there was a well marked ossific diathesis with a tendency

to affect the teeth as well as the other bony structures of the body.

The tooth imbedded in the exostosis is a small one, yet the tooth and tumor combined after two years' curing weigh five ounces.

The second molar had been crowded out of its normal position, rotating in its movement until its diameter from before back, and its diameter from side to side had changed positions, the external border coming into contact with the posterior border of the first molar. The relative position of the second and third molars are illustrated in Fig. 26.

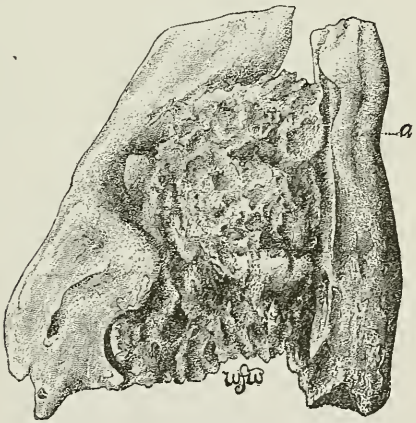

FIG. 26.

SECOND AND THIRD LOWER RIGHT MOLARS.

Showing the position the 2 had attained during the growth of the exostosis on the 3, *a* anterior proximal surface.

This tooth had no attachment whatever to the soft structures, but was retained in the mouth by the exostosis on the third molar.

CHARACTER OF THE EXOSTOSIS.

I have not been able to make out definitely the class of structure entering into the formation of the osseous tumor. During its growth it has enveloped such foreign substances as hay and hair which are now plainly visible. Nearest the tooth it has the appearance of crusta petrosa, while the more remote portions resemble a calculus deposit, not very firm in texture. That portion next the tooth however, has taken a very high polish from coming in contact with the teeth of the upper jaw which passed down upon the inside of the tumor. Had the tumor not been worn away by this friction it would undoubtedly have weighed at least two ounces more.

The osseous walls of the sinuses, also become the seat of osseous tumors—exostoses. The inferior maxillary sinus is most often the seat of this disease, although the superior maxillary and frontal sinuses sometimes suffer from a similar affection.

These tumors or exostoses present a variety of forms; some are entirely composed of bone, some of bone and cartilage, some of cartilage, and others bone and fungous flesh.

The first consists of a deposition of bony material between the bone and periosteum, to both of which

it firmly adheres. This form sometimes attains sufficient size to bulge out the walls of the sinus, giving it a rounded appearance, and in some instances breaking through the bone.

A case of this kind was brought to my notice where great bulging of the facial bones had taken place over the inferior maxillary sinus. When first seen, an opening had formed externally, which established communication with the tumor. The owner of the animal merely wanted an opinion at the time, wishing to have the operation, if one was necessary, deferred. He called again later and requested me to operate which I did. By this time a portion of the skin had sloughed away, exposing the exostosis to full view. A circular portion of bone was removed from over the exostosis, which was then removed by aid of the bone forceps. The cavity was dressed with antiseptic lotions, complete recovery taking place in a short time.

The second variety consists of bone and cartilage, with more or less fungoid matter distributed throughout its formation. It is the variety most often met with, frequently giving rise to a fetid discharge from the nostril on the side where it is situated.

The third variety is that composed of cartilage. This undoubtedly is the earliest stage of the two preceding varieties and by ossification, if left alone, is developed into bone, forming the true osseous tumor.

The fourth variety consists of fungous growth very firm and containing small spicules of bone. This form very much resembles osteo-sarcoma. It, like osteo-sarcoma has a malignant character, and seems to be dependent upon some constitutional diathesis. It is very rarely noticed in horses; cattle however, suffer occasionally from its effects.

Exostoses present a variety of external forms, varying from a soft, spongy and cellular mass to a very compact and dense osseous tissue.

SYMPTOMS.

These exostoses may exist for a very long time without giving rise to any serious symptoms. It is rarely that the presence of the disease is suspected previous to the bulging of the external walls of the sinus. Occasionally however, they exert a pressure upon the turbinated bones, causing more or less difficulty in breathing. It is only when the sinuses are opened up with the trephine that their presence can be definitely ascertained. Sometimes there will be a discharge of a fetid character taking place from the nostrils. Percussion will enable us to diagnose a filling up of the sinus, but as this may be due to a variety of causes, all of which present similar symptoms, we can not arrive at a true diagnosis.

The author has repeatedly found the sinus, especially the inferior maxillary, partially or wholly filled up with these bony growths, when trephining

for the purpose of removing teeth. The exostoses if solid very seldom do any harm until they exert undue pressure upon the teeth or walls of the sinus. I am inclined to believe from the frequent discovery of these exostoses, when trephining, that they are often the true cause of caries of the teeth, or inflammation of the dental periosteum.

CAUSES.

Exostoses on the walls of the sinus are due to both local and constitutional causes. The local causes are injury to the walls of the sinus by external violence, which either fractures the bones or sets up an inflammation of the inner lining of the sinus. Nature in endeavoring to assist the restoration of the parts, causes new bone cells to form, which greatly multiply, forming bony tumors of variable sizes, according to the extent of the injury. The constitutional causes would be the same as those which bring about the production of bony tumors in other parts of the bony framework, an ossific diathesis. We sometimes see colts that were born with exostoses upon certain parts of the skeleton. This is especially true of the inferior maxilla. We have seen numerous instances where there was an exostosis on this bone about the region of the anterior and the middle third, varying in size from a bean to an English walnut, and of various shapes; some oblong, others oval, and in some cases very elongated ones have been observed.

TREATMENT.

No treatment will completely arrest these growths, and a dispersion of an exostosis on the walls of the sinus can never be effected. Blisters and absorbents may slightly arrest their growth, but will not entirely cause its removal. It is not desirable to remove an exostosis, unless it continues to increase in size, and produce deleterious effects or is productive of serious inconvenience.

When it becomes necessary to remove the exostosis, it should be fully exposed. This may be accomplished with the ordinary trephine and separating saw, after having properly dissected away the soft parts; care being taken to prevent injury to the surrounding tissue. If the tumor is attached to the outer walls only, of the sinus, by removing the walls the tissues can be brought away with it. If attached to the internal walls of the sinus by a broad base, its removal is more difficult; the bone cutting forceps, Fig. 39 with the saw and bone chisel, will be necessary to accomplish its removal.

If the exostosis be cartilaginous or of a fungoid growth, a heavy pair of scissors will be strong enough to remove them. If a portion of the exostosis remains, the application of the actual cautery will prove beneficial by causing an exfoliation of the diseased portion. The Paquelin thermo-cautery is an excellent instrument for cauterizing. When the

latter treatment is pursued that portion exfoliating should not be neglected and allowed to fall down and remain in the bottom of the cavity, or it will set up an irritation which will produce a discharge of pus through the nostrils that will remain until the exfoliated portion is removed.

Dr. C. E. Sayre, professor of veterinary dentistry at the Chicago Veterinary College relates the following cases:

"During January, 1887, I was called to see a horse, the property of Mr. M. on Twelfth street. The history as given by the owner revealed the fact that the animal had received a kick on the lower jaw a year before, since which time there had been a slight discharge continually taking place over the region of the injury.

"On examination I found a small sinus under the third lower right molar which, by passing the probe, proved to be very shallow, not more than a half inch in depth. At the bottom of the sinus necrosed bone conld be easily detected. I suspected caries of the third molar, but by a careful examination of the tooth could detect no trace of disease. The gums adhered firmly to the tooth. I then concluded that there was a small sequestrum of necrosed bone and advised trephining and its removal. Dr. Drake who was with me at the time coincided with my views.

"After applying the twitch we proceeded with the

operation, using a ¾ inch trephine, cutting through and removing the external bony plate. We found underneath it a piece of necrosed bone, about as large as a good sized pea. We made a careful examination of the wound, but could not find that the sinus extended any deeper. The wound did very well, and in a few days healed up nicely, but much to our disappointment only remained so a short time, when it broke out and discharged the same as before. We were then very certain that we had made a mistake in our diagnosis, and that the tooth must be involved; yet examination by the mouth did not help us to diagnose the difficulty. However, we advised the removal of the tooth, but the owner of the horse would not consent. He then placed the animal under the care of Dr. Craig who said the tooth was perfectly sound, and that the sinus could be healed in a few weeks. After treating the horse for three months with no better results than ours, he was returned to the owner. The following November I was again called to see the horse, and could then pass the probe three inches into the pulp cavity of the tooth. This convinced the owner that the tooth was unsound, and I was asked to extract it. On account of the age of the horse (six years), the teeth being very long at this time, I decided to trephine and drive the tooth out. As we already had a sinus, all we needed to do was to enlarge the opening

which we did, and expose the fang of the tooth. Placing the punch on the tooth, a few heavy blows with the mallet drove it up into the mouth. On examination of the tooth after its removal we found the root ulcerated and covered with numerous small exostoses, and the entire pulp cavity diseased. The jaw was then examined and found to be slightly necrosed, also several small exostoses on the second molar which could be felt through the opening made by the trephine. I was about to place the punch on this tooth and drive it out, but much to my disappointment and disgust the owner would not consent. I could not convince him that the tooth was diseased, so had to abandon its removal, well knowing that time would verify my diagnosis. I never saw a case do better, and very much to my surprise healed up entirely. I could not believe that I had made a mistake, and time proved I had not. In a few weeks it broke out as before. It was not until March, 1888, that the owner consented to have the tooth removed. We found quite a different horse this time on which to perform an operation. Before he was very docile; now after one experience in the stocks he was almost unmanageable. However, I succeeded in trephining without much difficulty, but when the punch was placed on the tooth we found it impossible to strike it, on account of the head being kept in continual motion. The horse was then cast and the

tooth driven out. After this operation he became very vicious, so that it was dangerous to dress the wound. As a consequence, the jaw swelled very much. A poultice was finally applied when the inflammation subsided. We were then able to dress the wound, but it healed slowly, taking three months to recover. The jaw was left somewhat thickened. We applied blisters to this several times, and now it is so smooth that it is only by close inspection it can be detected.

I regard this as one of the most instructive cases that has ever come to my notice. It shows that there may be ulceration of a root of a tooth without any sensible manifestation of disease in the mouth, such as the shrinking of the gum away from the tooth, as we have heretofore been taught is always the case."

"A case very similar to the above occurred in one of my own horses. He was purchased in May, 1888, and had a discharge from the fang of the second lower molar of the right jaw. He had received a kick on the jaw about a year before. The horse being very nervous and determined we thought best to cast and place him under the influence of an anæsthetic. Equal parts of chloroform and ether were administered, and in twenty minutes we proceeded with the operation. An opening was made with the trephine over the roots of the tooth which was easily driven out with the punch and mallet. In

about half an hour the horse got up, but seemed quite weak for a few minutes. He quickly recovered however, and took his feed as usual that evening. He did very well, and I left for the West a short time afterwards, expecting to find him all right on my return, but much to my disappointment there was a slight discharge from a small sinus, which extended up towards the first molar. The tooth on examination by the mouth showed no evidence of disease. The horse was again cast and the tooth removed. No ulceration was present, but inflammation of the periodental membrane was well marked which would undoubtedly have resulted in ulceration. Recovery took place very slowly, but permanently. The wound could not be dressed on account of the viciousness of the horse.

"In cases of the above nature I should advise a complete operation at the first attempt, removing all the diseased teeth and bones, as horses invariably get very nervous and hard to handle after a second operation, and it is impossible to give them the care they require."

C. E. Sayre, D. V. S., relates the following case of an exostosis situated on an incisor tooth:

"I had a case of exostosis on the left lateral upper incisor, as large as a good sized hickory nut. The tooth itself was very soft, in fact appeared to be only made up of crusta-petrosa, and had worn away almost

to the gum and appeared perfectly sound. The gum was very much inflamed around it, and when I undertook to extract it, I found it very difficult to do so, and had to cut the alveolus on both sides before I could effect its removal."

Dr. W. L. Williams, of Bloomington, Ill., reports the following case of dental cyst:

"An eleven months old French draft filly of exceptionally good form, size and quality, was brought to our hospital suffering from extreme dyspnœa, and showing an enormous swelling of the facial bones on left side.

"The owner first noted signs of disease some two or three months previously, when upon sudden exertion slight dyspnœa was evident, and about the same time the bulging of the facial bones was noted, both of which symptoms increased rapidly up to date of admission to hospital.

"The central part of facial swelling was about two inches above the fang of fourth superior molar, and apparently was due to some affection of the teeth. There was no nasal discharge and nood or discernable. The general health and condition of the filly was good.

"It was decided to trephine into the enlargement, in order to determine the exact nature of the affection, and after passing through the ordinary thickness of bone, we came upon a hard, tooth-like substance

barring our way. A small opening at one side of the tooth tumor permitted the escape of about two pints of pale-yellowish serum.

"The opening through the facial bones was enlarged, exposing a large part of the surface of the dental tumor, a steel punch was placed against it, when with several sharp blows it was broken from its attachments. It was found impracticable to remove the tumor entire, so it was broken up by means of heavy bone cutting forceps and removed in pieces. The tumor was irregular in form and weighed about four ounces.

"The surrounding cyst from which the tumor had been removed and the fluid had escaped, had enlarged to such an extent, as to destroy all partitions between the sinuses on the left side, converting all into one great cavity completely occupied by the cyst which by its great size, had encroached upon and occluded the left nasal passage, and by pressure upon the nasal septum had crowded it over into right nasal passage, seriously diminishing it in extent, necessitating great effort in respiration.

"The inside of cyst was thickly studded throughout its extent with soft, rough pyramidal bony elevations ¼ to ½ inches in diameter at base, and ⅛ to ¼ inches from base to apex.

"On the outside the cyst was smooth, covered with mucuous membrane, and detached from the facial

cavity throughout the greater part of its extent, and was readily removed by means of strong dressing forceps. The removal of the cyst disclosed the sensory branch of facial nerve, entirely devoid of its bony sheath, stretching across the facial cavity.

"At points where the cyst walls were continuous with the facial cavity, the bony papillæ were carefully removed, and the entire cavity dressed with carbolized oil and iodoform.

"Improvement was prompt and rapid, healthy granulations appearing over the entire extent of the cavity. In about a week the walls of the cavity receded promptly, relieving the dyspnœa and decreasing the outward bulging, and on the twelfth day after admission she was discharged apparently on the safe road to recovery. Six weeks later the owner reported her as practically well."

CHAPTER X.

FOREIGN SUBSTANCES.

THEIR SOURCE, SYMPTOMS AND TREATMENT—FRACTURES OF THE TEETH—HOW CAUSED—MEANS OF EFFECTING THEIR REMOVAL.

It frequently occurs that foreign substances, such as sticks of wood, pieces of corn cobs, wheat, rye and barley beards become lodged between the teeth or in the gums. These substances may be forced between adjoining teeth or may become lodged crosswise of the mouth between the right and left rows of upper molars. Occasionally but rarely, sticks become lodged between the corner incisors. Where horses are fed corn, the cobs sometimes become lodged in the roof of the mouth.

SYMPTOMS.

Continual champing of the jaws; excessive flow of saliva, at first frothy, but gradually becoming clear and ropy. If of long standing the saliva will have an offensive odor, the result of disease of the soft structures coming in contact with the foreign substance. Appetite increased, sometimes ravenous, but the animal is unable to take any food; great thirst with difficult deglutition; rapid emacia-

tion, and general weakness if the foreign substance is not removed. On the whole, the animal after a few days presents a very dejected appearance. Examination of the mouth will reveal the true nature of the difficulty.

TREATMENT.

Remove the cause, and if the mouth is sore from having been lacerated, dress it with alum water two or three times a day for several days; allow plenty of soft food until the wound heals.

Barley, rye and wheat beards sometimes prove very annoying and troublesome by forcing their way into the soft structures of the mouth. When present they are usually found on the under surface of the tongue and in the gums, outside of the lower teeth. They produce irritation which is shown by more or less champing of the jaws, free flow of viscid, somewhat fetid saliva. More or less pain is evinced while eating. After their complete removal the mouth soon regains its natural condition. Animals that are troubled in this manner or that have sore mouths, should not be allowed to feed on straw which contains beards, as they are sure to prove a source of more or less annoyance to the animal.

Dr. Sutton, of Kalamazoo, Michigan, related a case to me where a piece of corn cob had become lodged between the right and left sixth upper molars. When brought to him for treatment it had suffered

for two weeks and was reduced to a mere skeleton. He readily diagnosed the trouble and removed the cause. The horse rapidly regained his former condition.

While practicing at Kalamazoo, Michigan, I was called to treat a mare that had been suffering for three days from some cause, which the owner was unable to diagnose. However he had attempted treatment and as a result the whole mouth was blistered from the effects of the medicine which he had administered. When I first saw the mare she was standing in the stall hanging the head and champing the jaws. There was an abundant flow of viscid saliva from the mouth which was ropy and presented a fetid odor. On making an examination of the mouth, I discovered a piece of corn cob lodged between the upper and sixth molars. It had become so firmly lodged that it was with some difficulty that I effected its removal. The under surface of the cob had been worn smooth by the continual motion of the tongue, which had as a consequence, become very much lacerated and swollen. The after treatment consisted of cooling lotion to the mouth and soft food for a few days.

*"The editor of *The Veterinarian* reports the case of a pony that came near starving from having a stick fastened in its mouth. No fracture of the

*Clark, Horses' Teeth, Page 201.

bone was produced, but the account of the case is worthy of insertion notwithstanding that fact, for it illustrates a class of mishaps to which the horse is subject. He says, (*Veterinarian*, 1855, p. 330):"

"A pony was turned into a pasture and was not seen for several days. The owner found it standing in the corner of the field looking dejected and thin, with a small quantity of viscid saliva escaping from its mouth. He took care of the pony for a few days during which time it took nothing but a little water, which it drank with great difficulty. Our attendance was now requested. Examination disclosed a stick about the size of one's finger, firmly wedged across the palate between the corner incisors. Its pressure had produced extensive sloughing so that the bone was completely exposed. The pain was so great that the animal stoutly resisted our efforts to remove the cause of its suffering. This, however, was soon done, and the parts being cleaned with tepid water, were afterwards dressed with tincture of myrrhae. Little after treatment was necessary beyond the daily application of the tincture, a mash diet and the substitution of oat meal gruel for plain water.

The following case was reported in the *American Veterinary Review* and is interesting in that it shows the varied symptoms which the presence of foreign bodies may produce.

DENTAL NEURALGIA.

BY MR. MACORPS.

*"An old horse had for about a week refused food, carrying his head down and resting the occiput upward against the lower border of the manger, as if trying to raise it. The patient was dull and listless, the mucuous membranes pale, the coat staring, the flanks retracted. At times the muscles of the neck were the seat of slight trembling, and he had convulsive movements, as if in great pain. Careful inquiry into the history of the trouble failing to throw any light upon the case or aid in the diagnosis, a minute examination of the mouth was made when a black foreign body was found projecting between the first two molar teeth of the lower jaw. This was knocked off with a chisel and hammer, and followed within an hour by complete recovery."

FRACTURES OF TEETH.

Fractures of the teeth sometimes occur and become a source of great annoyance to the animal. The fracture may arise from various causes and assume various forms. The tooth may be fractured longitudinally, through the center, or transversely through the crown, neck or fang. Sometimes the crusta-petrosa or external layer of enamel becomes separated from the main portion of the tooth. This latter condition I have frequently found present in colts from one to two years of age. Fig. 27 and

*American Veterinary Review, Vol. x., Page 272.

28 represent shells which have become separated from the tooth. They are very thin and only made up of cement and dentine. The symptoms presented in the two cases were similar; there was great emaciation, bulging of the cheek, quidding of the food, fetid odor emanating from the mouth; great difficulty was experienced in masticating the food. On examining the mouth large quantities of partially masticated food were found lodged between the two portions of the tooth. This had become sour and had a very disagreeable odor. After its removal the separated portion of the tooth could be easily felt and was removed with the forecps.

FIG. 27.

Portion of external layer of enamel which has become separated from a molar tooth. *a*, cross section. *b*, lateral view.

Fractures of the teeth may be produced in various ways. External injury such as a blow or a kick, biting gravel, small stones, sticks, nails, bolts, burrs, pieces of iron, &c. Fractures of the molars also frequently take place after the incisors have been dressed down, especially if enough has been removed to keep them from coming together. Longitudinal fractures of perfectly sound teeth are sometimes seen in young horses, the cause of which is rather imperfectly understood. I have on several occasions been called

FIG. 28.

to remove such teeth, the cause of their fracture being unknown. On examination after removal they appeared perfectly healthy. These cases always occurred soon after the tooth had made its appearance as a permanent one. Unless their organization was defective or their growth excessive, I am at a loss to account for the fracture. Transverse fracture of the root is usually the result of a kick. In such cases a sinus will form, opening on the external surface of the jaw. They give the animal much pain during the process of mastication. Fig. 29 shows a tooth with a fractured fang. The fractured ends are worn smooth by the constant movement of the root in its socket. The root remained in the alveolar cavity after the extraction of the crown. It was loose but was situated so far below the border of the gum that it was impossible to grasp it with the forceps. The instrument represented in Fig. 51 was then devised and made out of a piece of 5-16 toe calk steel. With it the root was easily removed.*

FIG. 29.

FOURTH LOWER RIGHT MOLAR. *a*, POINT OF FRACTURE.

*I would say that the above instrument is one of the best for removing roots that remain in the cavity and are too short to grasp with the forceps. I have two of them, one as represented in the Fig., and the other with the curve just the reverse.

TREATMENT.

The treatment consists in removing the fragments of teeth. This may be accomplished in various ways, either the forceps, elevator, or trephine and punch may be used, whichever best answers the purpose. If the tooth is carious and an upper molar, accompanied by a discharge from the nostril, it is best to use the trephine, even after the remaining portion has been removed. That portion which is absent may have passed up into the sinus, and unless removed will keep up a continual irritation, attended by a constant discharge (of a very fetid character), from the nostrils. Whole teeth occasionally pass into the sinus and produce serious results. I have never seen a case where a fragment of tooth had passed into the sinus but have taken whole teeth from those cavities. The after treatment will consist in keeping the parts clean and if trephining has been resorted to, the opening should receive proper attention.

During the summer of 1888 a large brown mare was brought to Dr. B. C. Thomas, D. V. S., of Chicago, which had been discharging from the right nostril for some time. The walls of the sinus were very much bulged. On examination he found the fourth upper molar split and the inside half gone. He easily extracted the other half and by exploring the cavity with the finger found it to be full of feed.

He then trephined the frontal and superior maxillary sinuses, and much to his surprise found the other half of the tooth in the frontal sinus. It was removed through the opening made by the trephine, the mare making a good recovery.

*"C. D. House, Veterinary Dentist performed an unusual operation on a 7-year-old horse, the property of Mr. J. T. Allen of Hartford, Conn. In 1876 a surgeon(?) made an incision in the right cheek and knocked out a large part of the fifth upper grinder. The violence of the operation, fractured both the tooth and the jaw, imbedding a large fragment of the former in the bone above the socket. A year afterward, the horse still suffering and discharging matter from the nostril, Mr. House was requested by Mr. Allen to examine, and if possible cure him. He failed however to discover the cause of the discharge, and it was not until the expiration of another year that he determined to probe the case to the bottom, the horse in the meantime having suffered as usual. Making an instrument of the proper size and shape, he introduced it into the nostril, seized the tooth fragment and drew it forth, the horse at that instant making a deep expiration, which blew out several fragments of bone, and a part of the root of the tooth. The animal made a good recovery."

* Clark's Horses Teeth.

CHAPTER XI.

DENTAL CYSTS.

One of the most interesting features in connection with the study of the teeth is the fact that they may be developed in almost any portion of the body. They are found in connection with the sinuses of the head; the temporal bones; the frontal bones; the base of the ear; the space between the angles of the lower jaw; the lumbar region; the testicles and ovaries and near the kidneys. These teeth may exist singly, in pairs or in clusters.

Dentigenous cysts contain fully developed teeth which closely resemble a molar tooth in all its parts. They are made up of the different structures entering into the formation of teeth which occupy their natural position.

The most common situation of these dental cysts is the temporal region at the base of the ear. They produce a fistulous opening from which there is a constant discharge of pus with no tendency to heal.

C. C. Grice, a veterinary surgeon of New York, reports a very interesting case of the development of a tooth at the base of the ear. He says: * "At

* Veterinarian 1867, page 392.

the request of Mr. Barnum, a merchant of our city, and the owner of a breeding farm in Westchester county, I attended a two-year-old colt, considered to be very valuable, as he comes from trotting stock. Mr. Barnum merely said the colt had a discharge from the base of the near ear, and that it had existed for ten months.

"I found the animal so very shy on account of the previous torturing of his attendants, that I could not approach him; therefore I had to cast him. The introduction of the probe failed to satisfy me that any foreign body existed there, but on dilating the orifice and introducing the most reliable of all probes, my fore finger, I discovered a hard substance which was firmly attached to the temporal bone and surrounding parts. I could not grasp the substance with the forceps, therefore I used the handle of the instrument as a lever, and after using great force dislodged it. Mr. Barnum picked up something in the grass four or five yards from me and it proved to be a molar tooth. On examining the wound afterwards I found some loose fragments of bone, and on removing them they appeared to be the socket of the tooth. These parts have entirely healed and left no blemish."

The development of teeth in the sinuses of the head is a rare occurrence, yet I have been fortunate enough to see one such case. The subject was a

mare seven years old and well bred, the property of Mr. Clark, of White, Dakota. There had been a discharge of pus from a fistulous opening opposite the superior maxillary sinus which appeared several months previous to my being called to see the case. Prior to the discharge there had been a gradual bulging of the bones of the face over the region just described. On passing a flexible metalic probe into the fistulous opening it met with some resistance under the bones forming the walls of the sinus. By moving the probe it passed over considerable surface which appeared rough and indented. I was unable to correctly diagnose the condition which existed, believing it to be some form of a bony tumor or an exfoliated portion of bone. I next examined the mouth and found the teeth all in a healthy and natural condition.

An opening was made with the trephine over the diseased portion of the sinus, and the diseased cavity was exposed to view. A rather large tumorous appearing substance was noticed but could not be thoroughly examined owing to the interference of the blood. The tumor was detached with a heavy pair of cutting forceps and on examination proved to be an imperfectly formed molar tooth, with its crown nearest the external wall of the sinus. The wound was dressed and directions left for future treatment and a request to report the results

of the operation, but I have been much disappointed in not learning the results of the treatment.

It not infrequently happens that a second and third operation has to be performed, for a tooth again develops in the same place. Should this be the result the opening rarely closes.

A very interesting case recently came under my observation where a dental cyst had formed just below the ear. The subject was a mare three years old, the property of A. E. Strong, of Vicksburg, Michigan, and had been discharging pus from a cavity the opening of which was one-third the distance from the base toward the apex of the ear. At the time my attention was directed to the diseased condition the discharge had existed for about six months, the owner of the mare thinking it would soon heal. A physical diagnosis revealed the outline of the cyst, which was very superficial and easy to remove.

The formation of teeth in the various parts which have been mentioned, seem to follow the same general law in their development as those which appear in their proper places. They force their way towards the surface and establish a communication in that manner with the external surface of the body. It is self-evident that this action is not the same as that which results from the presence of a foreign substance. Though one of these encysted

teeth may be considered as a foreign body, yet it possesses inherent vitality. It is supplied with blood and with nerves and is covered by periosteum which has the power of secreting the cementum. It possesses all the elements necessary to produce a healthy growth of all the structures which go to make up the tooth. Indeed the teeth in dentigenous cysts are always sound themselves, no case to my knowledge being on record where they were found carious. I have seen a goodly number of such teeth which have been removed by various surgeons but never saw any other than a perfectly sound one.

We frequently find that foreign substances which have become lodged in various parts of the body become encysted and produce no bad results.

Abdominal pregnancy furnishes us an excellent example where a body foreign to its location may exist for years and produce no bad results. Two cases of this kind have come under my own personal observation where sows did well, thrived and fattened as though nothing unusual had happened. I have in my possession at present two pigs which were in the abdominal cavity eighteen months, were fully developed encysted, and gave no trouble to the animal. The owner of the hog was not aware that anything unusual had occurred until the animal was butchered for market. The above does not clearly belong in a work of this nature, yet it admirably

illustrates that substances foreign to their position do not always cause trouble simply because they exist.

In view of these facts it appears as though teeth developed in other parts of the body than the mouth do not cause a fistulous opening because they are foreign to their location, but that they follow the same law of development and after a certain period, in their effort to reach the surface, destroy the soft tissues which impede their exit, the same as any other teeth. I have seen a discharge take place in a number of instances over the region of the canine teeth when about to make their exit.

Why these teeth should develop at all outside of the mouth is a mystery which as yet needs a satisfactory solution, especially when located in the lumbar region, the ovaries and testicles. Their appearance in the sinuses can be traced to a definite source and I think is satisfactorily explained by Professor Williams, who says: * "To understand the process by which these tumors are formed, it is necessary to remember that the teeth of all animals belong to and arise from the membranous portion of the digestive canal and that at a very early period of fœtal life provision is made for the development of the permanent teeth as well as the temporary. This provision according to Goodsir, who devoted much of his attention to the subject is as follows: 'As early as

*Principles and Practice of Veterinary Surgery, page 430.

the sixth week of intra-uteral life (in the human fœtus), a groove appears along the border of the future jaws, called the primitive dental groove, which is lined by the membrane of the mouth. At the bottom of this groove projections—papillæ—spring up, corresponding in number with the temporary teeth; these gradually increase in size and acquire the shape of the future teeth.

Whilst the growth of the papillæ are going on, partitions are formed across the groove by which they become separated from each other. These partitions subsequently form the bony sockets.

The formation of these partitions places each papilla in a separate cavity. Concurrent with this process small growths take place upon the membrane of the mouth just as it dips into the papillary cavity or follicle which finally, by union with other growths, form a lid which covers the papillæ in a closed sac or bag.

Before a final closing of the follicle, a slight folding inwards of its lining membrane takes place. This folding inwards of the membrane of the primitive groove is for the purpose of forming a new cavity—*the cavity of reserve*—which furnished a delicate mucous membrane for the future formation of the permanent tooth.

From a study of this, it will be found that the cavity in which a permanent tooth is developed is a

mere detachment from the lining of the primitive groove by the formation of a fold in the lining membrane and that in this cavity a papilla is formed exactly in the same way as that of a temporary tooth. Now I look upon the formations of these dental tumors as being due to some eccentricity in this folding of the lining membrane, by which the cavity of reserve is made up of several folds; that these folds become eventually separated from each other, forming separate cavities of reserve; and that a papilla becomes developed in each cavity thus formed in a manner similar to those constituting the papilla of the natural tooth. These irregular papillæ become finally converted into irregular which for want of space in the mouth are forced upwards into the antrum (sinus), and may completely block it up as well as the posterior opening.

"I have classified them as cystic tumors, as, in the first instance they are inclosed in sacs or cysts; they however, soon burst through their investing membrane and form a large tumor, composed entirely of teeth, having a great variety of shapes and running in different directions. The teeth vary in size, some being very small, others nearly as large as a permanent molar. Each tooth has a pulp cavity, and is composed of the same structures as the natural teeth."

CHAPTER XII.

TARTAR.

HOW FORMED—ITS EFFECT ON THE TEETH—LAMPAS—CAUSE, SYMPTOMS AND TREATMENT.

Tartar is composed of earthy salts and animal matter. Phosphate and carbonate of lime and fibrin or cartilage are its principal ingredients; a small quantity of fat also enters into its composition. The relative proportions vary in different animals and also in the same animal.

All teeth are subjcct to tartar but not alike, it being deposited to a very great extent on some, while on others it exists only in small quantities. It collects on the teeth of some animals in greater abundance than on those of others, and its chemical composition and physical characteristics are exceedingly variable. In some horses it is very hard and is then almost wholly composed of earthy ingredients; in others it is soft and easily crushed between the fingers. In such cases it contains a greater per cent. of animal matter.

Its color varies in different animals; in some it is a dark brown or nearly black; in others pale yellowish brown, and in some instances nearly white.

Several theories have been advanced with regard to the manner in which the deposition of tartar takes place. The most satisfactory and at present generally accepted theory is that it is precipitated from the saliva, as that fluid enters the mouth, upon the surface of the teeth opposite the opening of the ducts from which it is poured. Particle after particle is deposited until it accumulates in such quantities that the whole tooth is almost or entirely encrusted with it. This is particularly noticeable in connection with the canine teeth, which very often are entirely covered with the secretion.

EFFECTS OF TARTAR UPON THE TEETH, GUMS AND ALVEOLAR PROCESSES.

The effect of tartar upon the teeth varies to a considerable extent. Some animals never seem to suffer any inconvenience whatever, while in others there is more or less irritation constantly present. This is shown by tumefaction of the gums and I believe in a good many instances gives rise to the condition known as Lampas, when occurring in old horses. Diseased gums and the destruction of the alveolar processes, and the loosening and complete loss of the teeth are among the resulting effects of its deposition. When deposited close to the gum it by slow additions gradually forces the gums and periosteum away from the tooth. After this it acts as a foreign substance and nature en-

deavors to rid itself of the offending object. Inflammation is set up with the gradual formation of pus, which may exist in large or small quantities. I have on several occasions removed molars with my fingers, where there was a complete separation of the tooth and soft structures. These teeth were always covered with more or less tartar which extended much below the surface of the gums, and in some instances were covered with pus. I have in my possession at present writing such a tooth which is completely enveloped with tartar, varying more or less in density on different parts of the tooth.

Another case came under my observation where the tartar had collected on the left upper central incisor of a horse in sufficient quantity and had penetrated to such a depth as to cause much tumefaction of the soft parts. On making a close examination a small piece of tartar was detected projecting through the gum about three-quarters of an inch from where the tooth emerged. This was drawn out and an incision made down to the tooth and several large pieces of tartar removed, which extended up to the alveolar projection.

TREATMENT.

The tartar should be removed when found to exist, especially if in sufficient quantity to affect the health of the animal in any manner. This may be

accomplished with the ordinary bone spoon represented in figure 30, which should be followed by the brush, an ordinary nail brush answering the purpose. Care must be observed and if possible

FIG. 30.

BONE SCRAPER.

every particle removed or it will form a nucleus around which deposition will again take place very rapidly.

LAMPAS—CAUSE, SYMPTOMS AND TREATMENT.

Closely allied to the subject of tartar is another condition which has received the name Lampas. This term does not convey a definite meaning of the condition to which it is applied, yet for the want of a better one it will have to be used.

Lampas is an unnatural tumidity of the bars forming the roof of the mouth, frequently involving the gums of both upper and lower jaw. The bars are pale colored and pliable during health, but in a mouth affected with Lampas they will swell up, become red and tumid, bulging downward even with, and often below the grinding surface of the teeth. They have lost their pliability and are much harder to the touch

than when in a natural condition. These symptoms are not confined to that portion of the mouth just back of the incisor teeth, but often exist in the bars between the molar teeth, where they escape the notice of the casual observer. The inside gums of the lower jaw, also the outside occasionally, are sometimes affected in a similar manner. First there is congestion and in some instances it is followed by more or less inflammation, sometimes—but rarely—terminating in suppuration. In young horses it is undoubtedly due to teething or external injury. In some instances aggravated cases have been observed in aged horses. The cause of its appearance in such animals, has not been satisfactorily explained up to the present time. Some ascribe it to the continuation of the growth of the teeth during life, others to the constant pushing up of the teeth from their alveolar cavities. It is due, no doubt, in some instances to external violence, such as a hard substance bruising the parts and separating the gums from the teeth.

The immediate or exciting causes of tumefaction of the gums are local irritation, produced by salivary calculus (tartar), by carious, dead or loose teeth, or roots of teeth. A projecting molar may be, and often is a source of irritation to the dental periosteum and gums, which gradually extend until the whole becomes involved. This may explain the

more frequent occurrence of Lampas in the upper jaw, for in the majority of cases, the loss of a tooth from natural causes takes place in the lower jaw, leaving the opposite tooth unopposed. It will then gradually force its way out becoming longer than the adjacent teeth. The irritation will be very much increased should the tooth occupy (which it frequently does), a position like that represented in figure 31.

Dead or loose teeth act as foreign bodies, as also do the roots of teeth where the crowns have decayed or been broken off. These set up irritation in their immediate vicinity which may gradually extend until a considerable portion of the gums become involved. Tartar forces the gums and the alveolar dental membrane away from the tooth, or a small particle of tartar may become detached and work its way in between the soft structures, producing irritation with a tendency towards suppuration.

TREATMENT.

First thoroughly examine the mouth and if possible ascertain the cause in order to effect its removal. If in a young animal and the tumidity of the gums be due to teething, and the teeth have not yet appeared, it would be well to lance the gums over and down upon the teeth causing the trouble, which in most cases will probably be the canine or sixth molars.

Such an operation is very often followed by the immediate subsidence of the symptoms. If due to tartar its removal should be effected in the manner already described; and if resulting from dead, carious or fractured teeth, remove them and bathe the mouth with a dilute solution of distilled extract of witch-hazel, carbolic acid and water. The solution should not contain more than one part of carbolic acid to forty parts of water and ten parts of the witch-hazel. In no case is it necessary to scarify or burn the gums to relieve the symptoms, for it only adds to the already existing irritation a foul, sloughy, carious sore, which can in no way ease the Lampas. The tumidity of the bars is the effect of the disease and not the cause, hence any treatment which is applied to relieve the effect must necessarily fall short of its object unless the cause first receives attention.

The true cause of unthriftiness in many cases of supposed Lampas, is some constitutional disturbance, existing independently of a diseased mouth, and requiring a different mode of treatment. A few doses of tonic or alterative medicine will usually relieve the symptoms in a short time.

CHAPTER XIII.

PROJECTING TEETH IN HORSES, SHEEP AND PIGS.

THEIR CAUSE, RESULTS AND TREATMENT.

There seems to be a difference of opinion among the various authors in regard to the length of time permanent teeth continue to grow; some maintaining that the growth of the tooth is completed by the sixth or seventh year, others by the tenth or twelfth year, while some contend that the tooth of a horse grows for a much longer period.

Clark, "Horse Teeth," page 73, says: "They, **permanent teeth* attain their growth more slowly *than the temporary*, and a healthy tooth continues to grow throughout life. The growth offsets the wear, the wear the growth.

If we carefully examine the above statement we can not conclude otherwise than that the tooth retains its length throughout life, for if "the growth offsets the wear, and the wear the growth," then it must necessarily follow that one end of the tooth is reinforced as fast as the other is cut away by attrition. This theory does not hold true in actual prac-

* Italics mine.

tice. If we extract a tooth from a horse eight years old, and compare it with a corresponding tooth that has been extracted from a horse sixteen or eighteen years old, there will be a considerable difference in their length in favor of the younger tooth. In aged animals there often remain only the roots of the teeth. These roots are very short and easily removed; had the growth offset the wear this would not have been the result.

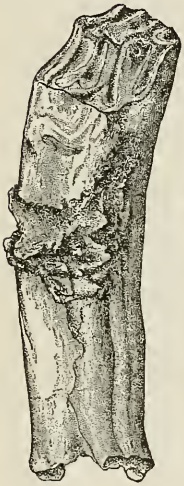

FIG 30.
A projecting tooth which has been extracted. The table surface shows the irregular wear to which it has been subjected.

* "It is not until the tooth begins to be pushed from the alveolus and the crown to become worn that its fangs are formed; these are at first hollow and afterwards filled, as well as the cavity of the tooth, by the formation of a new quantity of dentine. From this time the fang ceases to grow; but the tooth constantly projected beyond the alveolar cavity, allows the walls which enclose it to contract, so that in extreme old age it happens that the shaft completely worn away, instead of the tooth, leaves several stumps formed by the fangs."

† "The permanent teeth are thrust up from the

* Chauveau, Comp. Anat. Page 354. † Same, Page 349.

alveoli during the entire life of the animal to replace the surface worn off by friction."

If we combine the essential points of the last two statements we will see that the tooth ceases to grow at some period of life (just when, we are left in doubt), and that its free surface above the gums is maintained after the growth of the tooth ceases, by being pushed upwards from the alveolar cavity and the gums closing around it.

I formerly held the same opinion as that expressed by Professor Clark, that the teeth continued to grow throughout life, but since have had so many proofs of its erroneousness that I have very materially modified my views.

The following cut, Fig. 31, shows the fourth upper molar which has projected just one inch

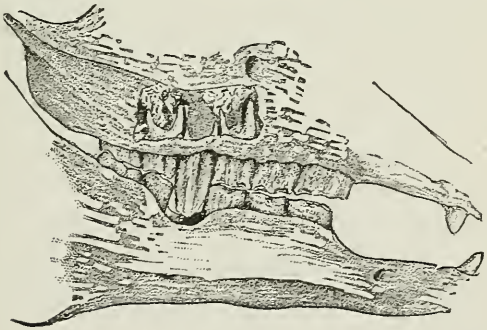

FIG. 31.

Molar teeth of the horse, showing a projecting fourth molar.

beyond the teeth on either side of it, owing to the loss of the corresponding tooth of the lower jaw. There can be no doubt that it was the direct cause of the animal's death, it having cut deep into the lower jaw, and even worn away a considerable portion (three-quarters of an inch) of bone.

If we examine the cut closely we will notice that the roots do not extend within three-quarters of an inch as far up into the alveolar cavity as those of the teeth on either side. Taking the difference of measurements of the projecting tooth and those on either side, and we have one-fourth inch more on the crown of the projecting tooth than would otherwise have been there had the tooth constantly remained in wear.*

The drawing for the above cut was made from one of many specimens that I have in my possession, all of which are deemed as convincing proofs that the teeth do not continue to grow during life.

It is difficult to determine the exact time at which the tooth ceases to grow. I have endeavored to collect the opinions of some of the best veterinary anatomists in this country, and for this purpose the following questions were sent out:

First—How long are the permanent teeth of the horse in developing?

* The fact that the roots of the fourth molars are always shorter than those of the third and fifth must not be lost sight of in making a comparison. The difference amounts to from one-fourth to five-sixteenths of an inch, as shown in Fig. 32, which was drawn from a perfectly healthy mouth.

Second—At what age do they cease to grow, or do they grow throughout life?

Third—If they cease to grow, how is their free surface maintained?

Drs. Hughes, Grange and Liautard responded, and their communications are here inserted:

Joseph Hughes, M. R. C. V. S., Professor of Anatomy at the Chicago Veterinary College, says: "I would say that at one time I was particularly

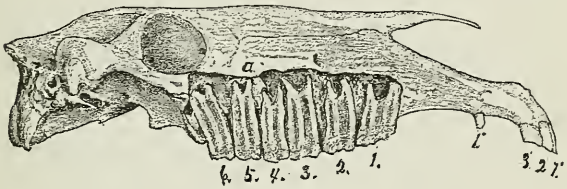

FIG. 32.

Upper jaw, showing the roots of the molar teeth; 1", canine; 1', 2', 3', incisors; 1, 2, 3, 4, 5, 6, molars; g, fangs of fourth molar.

interested in that question, and sought every opportunity to determine as to when molar teeth stop growing. I proved this much to my satisfaction. As soon as a molar tooth is fully erupted and comes into wear, the pulp in the cavity commences to shrink, and in doing so produces layer after layer of yellow osteo-dentine. The shrinkage still continuing, the pulp cavity soon becomes filled and at the same time the fangs commence forming, being produced by the pulp which is almost completely atrophied by this

time. So long as it exists however, it continues to form dentine, thus drawing out the fang to a tapering point. When this occurs all nutrition, in my opinion, is cut off from the tooth, so that it can not be regarded otherwise than a foreign body, firmly clasped by the gum and alveolus, and continually pushed upwards by the contraction of the plates of bone which become thinner as age advances. I would say that at from seven to nine years a tooth has attained its fullest growth."

E. A. A. Grange, V. S., Professor of Veterinary Science at the Michigan Agricultural and Mechanical College, says: "I believe the development of the teeth varies with the individual, and am inclined to think they stop growing at the fourth or fifth year. (**The horse would then be seven to nine years old*); though I would not be surprised if it was subject to considerable variation, but I do not think that they continue to grow throughout life, say beyond the twelfth year."

A. Liautard, M. D., V. S., Professor of Anatomy at the American Veterinary College, says: "Permanent teeth are in the state of development, until they make their appearance through the gums which close their alveolar cavity; but though developed they then begin their growth outside the cavity and owing to their situation begin to grow out at two

* Italics mine.

and one-half to three; three and one-half to four years, and their full growth can be considered at the time when the tables of the teeth are in perfect contact. The growth however does not stop at that time. I believe their growth out of the alveoli keeps on going if opposed by the rubbing of a tooth opposite; an even wearing takes place if nothing arrests it; or if there is no wearing the tooth keeps on growing out of its cavity and may overlap or overgrow the other teeth by inches. In other words the free part after having reached its full development, if not exposed to wear, is growing. The tooth becomes too long, but its length is made at the expense of its root which becomes shorter. Take a tooth which has not been in wear, as in the case of the opposite being removed; let it grow to its utmost, then pull it. Its roots will be very short. Again take one which is softer than normal, it undergoes an excess of wear. When it is projecting but little, extract it and the roots will be correspondingly longer. And then again take that of a very old horse in which the wearing has been perfect and then both roots will be very small."

It is of great importance in operating that we should know when the tooth ceases to grow, for operations may be performed on a full grown tooth that would not be admissible where the pulp exists to any considerable extent. The pulp is highly supplied

with nerves which come from the fifth pair and are very sensitive, and it is owing to its extreme sensibility that toothache is so severe when the pulp is exposed.

FIG. 33. Open molar cutter.

TREATMENT.

There are two methods of dealing with long teeth, one by extracting and the other by cutting the tooth down even with the other teeth. The age of the animal will be an important element in deciding which course to pursue. If but four or five years old the tooth should be extracted, which may be accomplished with the common heavy extracting forceps. If the tooth is cut off at this age there is danger of exposing the nerve and severe toothache would result; caries would soon supervene, making the entire removal of the tooth necessary.

If the horse is seven years old or over, the tooth may be cut off with the open molar cutters. Fig. 33.

It should then be dressed smooth with the float so that the soft structures of the mouth which come in contact with the tooth, will not become irritated and ulcerated.

If the tooth is cut off it should be looked after at least once each year, for it gradually protrudes

again and needs to have the operation repeated. Extracting on the whole is deemed preferable, although it seems rather formidable. A long tooth even if sound is not nearly as hard to extract as those on either side of it which have remained in constant wear.

The reason of this is obvious, for if we examine the roots we find they do not extend nearly as far into the alveolar cavity as those on either side, neither are the roots as long. They thus afford less surface for attachment to the side of the alveolar cavity.

There is another important element that should not be lost sight of even if the projecting tooth is extracted. It very frequently happens that the tooth of one jaw does not come wholly into opposition with the corresponding tooth of the opposite jaw. In such cases either the anterior or posterior edge of one of the teeth in the jaw opposite from that which had the tooth extracted, will still remain out of wear and as a consequence will gradually project, often producing a very sharp point which lacerates the lips very severely. These points should be removed and the mouth carefully examined thereafter at least once a year.

Difficulty may also arise, and frequently does, from the teeth on either side of the cavity, formed by extracting the tooth, closing in and partially fill-

ing up the space. In this manner one edge of them comes more or less out of wear, and results similar to those already described may follow.

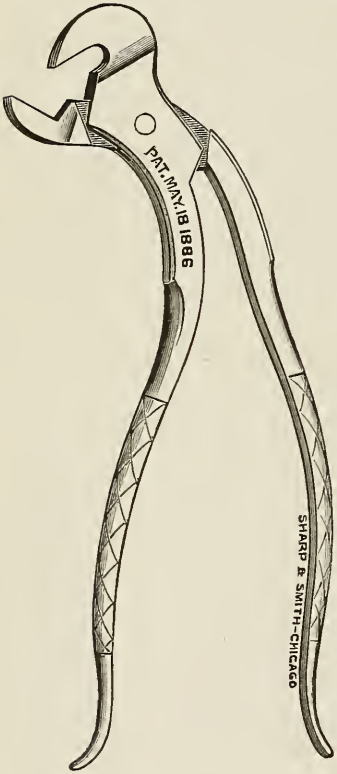

FIG. 34. Incisor cutter.

The question often arises: "Is an animal with missing or diseased teeth unsound?" I should say most decidedly that he is, for more or less trouble will ever afterward be experienced in keeping the teeth in proper shape and the animal in good condition. Although strictly speaking, it is perhaps not an unsoundness, yet it leads to disease which will materially affect the usefulness of the animal, unless carefully watched and subsequent defects removed.

The incisor teeth occasionally need to be shortened more or less, especially if the horse is not allowed to run to pasture, and is fed on hard food

such as whole corn and oats. The molars do not come together near enough to thoroughly grind the food and a portion of it will pass through the animal undigested. The teeth should be thoroughly examined and if they are in a proper condition and the animal does not bolt his grain, it is perfectly safe to operate on the incisors.

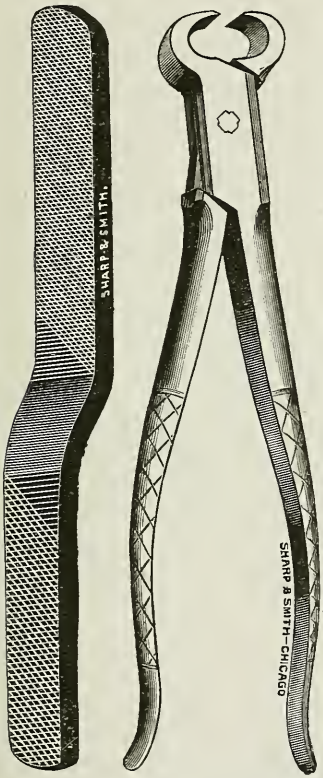

FIG. 35. Tooth file. FIG. 36. Straight cutting forceps.

The instruments necessary to operate on the incisor teeth are the curved incisor cutters, Fig. 34, and a ten inch tooth rasp. This is made in two styles, one which is straight, and another as in Fig. 35, which is bent at right angles at the center. Either one does the work. I prefer the straight one.

With the curved incisor cutters remove the inner border of the incisor, and with the straight incisor cutter, Fig. 36, remove the outer border; then smooth with the rasp, being careful to keep the table

surfaces so that all the teeth will meet and match perfectly. The operation is usually confined to the incisors which are abnormally the longest, *i. e.*, if the upper incisors are the abnormally longer, operate on them; if the lower are the longer, operate on them; and when the teeth of both jaws are of equal length, operate equally on both upper and lower.* Care, however, should be observed and not too much removed or fracture of the molars will result. They will also wear away much faster than they would if the incisor teeth are left a proper length.

The operation is seldom necessary, although I am am aware it is often resorted to, as a means of allaying symptoms which belong to a vastly different affection.

PROJECTING TEETH IN SHEEP.

Long or projecting teeth are often the true cause of unthriftiness in sheep. They seem to suffer from its effects oftener than any other of the domestic animals; yet there are very few owners of sheep who are aware of this fact. Very few people owning sheep ever think of examining the molar teeth for the purpose of determining the true cause of the unthriftiness of portions of their flock. I have never had my attention directed to this class of patients by the owner of such animals, neither has any one mentioned the subject to me up to the present time.

* We should bear in mind however that the upper incisors when natural are somewhat longer than the lower.

My observations have been limited, but enough has been seen to convince me that many dollars' worth of sheep die annually from this cause alone.

Not long since I came across three carcasses of sheep that had died (did not learn their history), all of which had suffered great emaciation at the time of their death, they then being mere skeletons. The heads were removed, boiled and prepared for the museum. In all were found diseased teeth. Fig. 37 and Fig. 38 are from drawings of the teeth of two of them, the third being in the same condition. Since preparing the above specimens my observations on the living animal

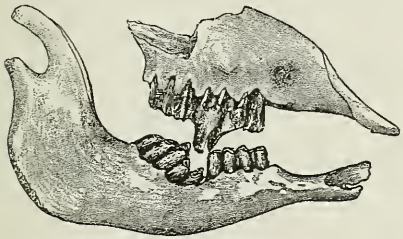

FIG. 37.
Upper and lower molar teeth of the sheep, showing a projecting molar.

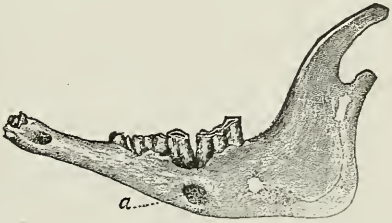

FIG. 38.
Lower molars of a sheep. *a*, a cavity, the result of an abcess.

have convinced me that long and projecting teeth are the direct cause of much unthriftiness, also that they are not confined to old sheep alone, but that they do exist in young sheep to a greater or less extent.

SYMPTOMS.

There is more or less flow of saliva, ropy, clear and watery; hanging of the head; dejected appearance. The affected animal will often stand apart from the rest of the flock; after a time there is emaciation which gradually increases until the cause is removed or death takes place. The mouth will be swollen, red, hot and tender to the touch. An enlargement may or may not exist on the external surface of the jaws. A foul, disagreeable odor will emanate from the mouth. There is also a stench of all the buccal secretions, due in part to the decomposition of the food which lodges around the projecting teeth. Some animals quid their food, others eat heartily for a time, then stop suddenly, drop the food out of the mouth, hang the head or hold it to one side; others will twist the head sideways while feeding, grinding all the feed on one side.

TREATMENT.

The treatment will consist in extracting or cutting off the projecting tooth, the common bone cutter, Fig. 39, will answer the purpose if cutting them is deemed preferable. When it is necessary

to extract, the smaller extracting forceps will be found sufficient for all purposes. The after treatment will consist in keeping the mouth free from offensive odors by the judicious use of carbolic acid and water, and allowing soft food for a few days.

PROJECTING TEETH IN HOGS.

Hogs sometimes suffer from projecting molars as well as from long tusks. The tusks instead of growing outside of the lips, grow upon the inside,

FIG. 39. Bone cutter.

press against them, cutting deep cavities, so that the animal will be unable to take his feed. There will be gradual emaciation with symptoms similar to those of other animals which are affected in a similar manner.

TREATMENT.

The treatment will consist in removing the offending teeth in a manner already described for similar defects of other animals.

CHAPTER XIV.

LONG, SHARP AND PROJECTING EDGES.

THEIR CAUSE, EFFECTS AND REMOVAL—SPECIAL OPERATIONS — SIDE LINING — SHYING — RUNAWAYS — METHOD OF OPERATING FOR EACH.

Horses of all ages suffer more or less from long, sharp and projecting points which are often found on the molar teeth. They are situated on the inside of the lower and on the outside of the upper molars, and also occasionally, but rarely, on the inside of the upper molars. They vary much in size and shape, some being small and blunt, while others are long and very thin and sharp. The injury they produce will be in proportion to their length and the thinness of their edges or the sharpness of their points.

The external surface of each upper tooth usually contains two of these projections, which correspond with the ridges already described as running from the table surface to the roots of these teeth.

The internal surface of the lower molars also contains two sharp projections, which usually are much shorter though sharper than those on the upper teeth.

These projections are the result of limited lateral motion of the lower jaw. In masticating its food

the animal works the lower jaw from side to side. Unless this motion is extensive enough to bring the whole table surface into wear, a portion of the tooth will not be worn away.

In some animals the width of the upper jaw (which is always wider than the lower), exceeds that of the lower to such an extent that it amounts to a malformation. Cases of this kind have come to my notice where only half of each row of teeth came into wear, and that portion remaining out of wear had become so long that it bruised and lacerated the gums of the opposite jaw. The lower teeth passing inside the upper had cut deep cavities into the palatine processes.

This defect may exist in both the right and left side, or on one side only. I have seen two instances where the latter condition was present in the living animal.

Case 1. A sorrel gelding, the property of a Mr. Williams, Goodland, Ind. The left lower row of teeth was inclined inwards as well as upwards; their internal surface not coming into wear, had continued to increase in length until they penetrated the palatine processes. The external surfaces of the lower molars were worn down to the gums. A like reverse condition was present in the upper molars; the inside of them being worn away while the outside had attained sufficient length to lacerate

the external surface of the gums opposite the lower molars. These sharp projections were removed with the tooth shears. The animal although much emaciated, rapidly gained in flesh, and when last heard from was doing well.

Case 11. A brown mare, the property of Mr. ——, Bangor, Michigan, to which I had my attention directed, had suffered from a diseased mouth for two years (she being at the time seven years old). There was a constant dripping of a ropy saliva, presenting a disagreeable odor, accompanied by great emaciation. An examination of the mouth found the fifth and sixth molar teeth of both upper and lower jaw similar to those in case 1, the inclination of the sixth molars being much more marked than in the fifth. The sixth molars of both jaws were cut close to the gums while the fifth were dressed down even with the teeth in front of them. Extraction of the sixth molars is preferable in cases where the teeth in front of them retain their natural position.

* There is in the museum of the College at Alfort, a horse's head in which this deformity may be seen in its greatest degree. The tables of the teeth at the right side form planes so much inclined that they close together like the blades of shears. As there was no friction to wear the teeth down,

* Clark, Horses' Teeth, Page 142.

they grew to the height of three inches. The fourth and fifth teeth of the right side of this rare anatomical specimen are absent. Perhaps they were carious. The rarefied and spongy tissue of the socket bones indicate the seat of an alteration,—probably caries—which was the point of departure of the general tumefaction. The last tooth by its oblique direction towards the empty sockets, indicates that the loss of the teeth occurred during the life of the animal, some time perhaps prior to its death. The defect of the right side doubtless forced the animal to use the left for the purpose of mastication. In such cases the teeth that do not wear, grow till they reach their respective opposite jaws, even when those at the opposite side of the mouth are in exact contact, an anomaly never produced in the normal state. The function of mastication operates according to the obliquity of contact and parallelism is established by friction between the tables which normally would be superposed."

The following case was reported in the *American Veterinary Review* Vol. IX., p. 321:

IRREGULAR WEARING IN THE MOLARS OF A HORSE—NECROSIS OF THE PALATINE BONE.

DESCRIPTION OF A SPECIMEN PRESENTED BY B. MCINNESS, JR. V. S., TO THE MUSEUM OF THE AMERICAN VETERINARY COLLEGE. BY J. SCHRIEBLER, D. V. S., CURATOR OF THE MUSEUM.

"The preparation exhibited was the head of an old horse which had been the property of an aged

South Carolina negro. When death occurred the horse had become so emaciated that his appearance was almost like that of an animal which had died of starvation. The condition of the teeth to a great extent explained this fact, and showed the difficulty the animal must have experienced in masticating his fodder. The molars of the left side on both jaws were about normal, but those of the right presented a very peculiar aspect, due to an irregularity in the wearing process, which instead of taking place flatwise had affected the teeth in their length. Those of the upper jaw were worn from above downwards and from the inner side outwards, in such a manner that while the outer surface of the teeth measures over two inches, the inner surfaces measure scarcely half an inch, this being about the normal length of the teeth. This irregularity is perfectly smooth on the inner surface for the first four molars, but irregular on the fifth, which is angular. These teeth and the last have undergone less wearing. On the same jaw the palate bone was already undergoing necrosis, and showed in the center a perforated appearance and a depression towards the back. This condition of the palate bone is due to the action of the molars of the lower jaw. In that region the left molars are also healthy, but on the right side the first, second and third have undergone a process of wearing, corresponding to that of

the upper jaw, but in an inverse direction. The third one which has a length of nearly two and one-half inches has produced the depression in the palate. The fourth, fifth and sixth molars are missing in the specimen. It is probable that the fourth was lost in preparing the head, but there is no doubt that the fifth and sixth were lost during life, as can be seen by the wearing out of the outside surface of the alveolar cavities, and their almost complete disappearance. This is the second case of this kind that has come under our observation. The first however, was more complete, as the irregularity of the teeth existed on both sides and both jaws. When the animal died all the teeth were not only found on both sides of both jaws, but the animal presented also an abnormality in the number of teeth, having twenty-eight instead of twenty-four molars. This irregular condition of the teeth furnishes a ready explanation of the difficulty of mastication, and can scarcely be relieved, except by bestowing a degree of attention to the organs which it is not yet usual to bestow on animals."

The sixth molar of either jaw, may and often does, extend back of the corresponding one of the opposite jaw and when such a condition exists, the projecting portion not coming into wear, is continually increasing in length, by being projected outwards until it wounds the opposite jaw. This condition is

present more frequently than is generally supposed; and when present is most often found in connection with the sixth molar of the lower jaw. These points should be removed. It may be accomplished in the same manner as other sharp and projecting points. The wounds made by these projecting points often become very troublesome, and remain for a long time after the cause has been removed. To facilitate their healing, touch them with a stick of nitrate of silver (lunar caustic) once a day for two or three days, or a wash composed of alum, sulphate of zinc (white vitriol), and distilled water may be used. The nitrate of silver is preferable and most easily applied. Keep the animal on soft food for a few days and occasionally cleanse the parts with a soft sponge.

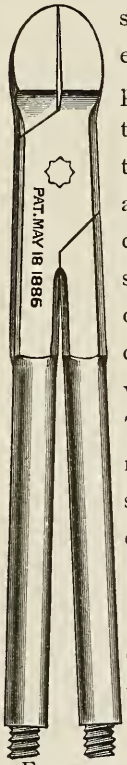

FIG. 40. Closed molar cutter.

TREATMENT.

In removing the sharp projecting edges, either the rasp and closed molar cutters, or the rasp alone may be used. The closed molar cutter, Fig. 40, is an excellent instrument for facilitating the work. The outside of the upper and the inside of the lower molars may be clipped and then smoothed with the tooth rasp, Fig. 41. There is practically no danger of fracturing the teeth

FIG. 41. HOUSE'S REVERSIBLE RASP.

with the cutters if judiciously handled, and not allowed to grasp too much of the tooth.

The plates of the tooth rasp if separate can be removed and new ones substituted at any time when the old ones become worn out. Fig. 42 represents one of these rasps. For convenience in carrying, the handles may be made with a joint so that they can be separated.

If it is not deemed advisable to use the cutter, a rasp which is punched will cut away the tooth much faster than a cut rasp, but its use should be followed by a smooth rasp.

SPECIAL OPERATIONS.

Horses which are put to different uses require operations on their teeth that will fit them for the work which they are required to perform. We should aim to put the teeth in such a condition that they will not lacerate the tongue and cheeks. In trotting and running horses which often get excited, or that have the bit frequently shifted, there is a tendency to cut the cheek opposite the first upper or lower molar. This is very often prolonged to such an extent that the animal becomes unmanageable and utterly useless for the work he was intended to perform. If such a condition is present in

FIG. 42. HOUSE'S REVERSIBLE RASP, JOINTED.

a trotting or running horse they will not take hold of the bit freely. Sometimes they "bolt," pull on one line, run into the fence, stop short or perhaps collide with another animal and injure both.

In operating on horses of this kind it is best to cut the first molar, usually the lower, well down and in some instances the second molar should also be slanted from before backwards and upwards. The teeth are then to be rounded from side to side and left as smooth as possible, so that the tongue and cheeks, though they are drawn between them, will not be injured.

The driver or rider of a horse should always be consulted about the actions of a horse while at work, before the operation is performed. They are an element which should not and can not be ignored by the veterinary dentist if he wishes to be successful in relieving the symptoms for which he operates. Sometimes an operation is needed on one side of the mouth only; in such cases, cutting down the teeth on both sides would be as bad, if not worse, than no operation at all.

Horses that are in the habit of running away while being driven, in the majority of

cases can be entirely cured of this habit, by cutting away or extracting the first lower molar. By doing so it deprives them of a solid support for the bit which will then draw directly against the angle of the mouth. Before operating in the above manner (which should be as a last resort only), it is well to examine the edges of the molars, and if rough, dress them down smooth.

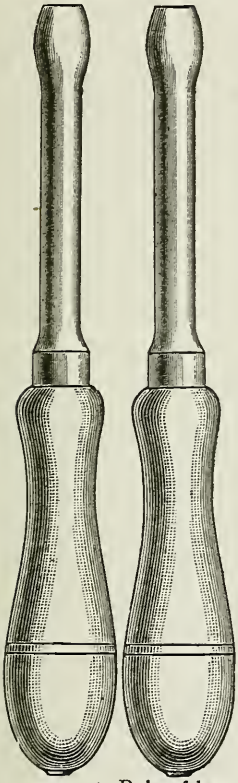

FIG. 43. Pair of handles for extracting forceps and molar cutters

Another very disagreeable habit, the result of sharp teeth and which can be entirely remedied, is known as "side lining" or "side pulling." It consists in the horse carrying his head to one side, or pulling harder on one rein than on the other while being ridden or driven. Horses addicted to this habit are known as "side liners" or "side pullers."

The first step in remedying this defect is to dress the inside of the lower molars and the outside of the upper ones. If this does not have the desired effect, cut off a portion of the lower first molar, on the side opposite from that towards which he carries his head. That is,

if the horse carries his head towards the right side, cut the tooth on the left side and vice versa. This removes the bearing and the head will then be carried in a natural position.

I usually place the cutters close to the gums of the lower molar on which I wish to operate and then cut backwards and upwards. The amount of tooth which I remove depends upon the age of the animal and the persistence with which he throws his head to one side.

In using the cutter place them squarely upon the tooth and cut it off without shifting or twisting them. By so doing you will avoid fracturing the tooth, which sometimes does occur if the forceps are worked from side to side.

It is claimed that sharp points with other irregularities of the teeth cause a horse to shy. I will say that as far as my experience extends, I have never been able to trace a single case of shying to such conditions, neither have I ever stopped shying by operating on the teeth, unless the horse was a "side puller." It has been my experience that when such horses shy it always is from an object towards which the horse turns his head (*i. e.*, if a horse turns his head towards the right he shies away from an object on the right). I have had three such horses as drivers, and they invariably shied in the same direction, and that as above described.

The shying in such cases is undoubtedly due to imperfect glimpses of objects on that side, for in all three cases of my own, when the teeth had been operated upon so that the horse carried his head straight the shying disappeared. Shying however, is not always due to the above cause. It is sometimes due to congenital malformation of the eye, such as near-sightedness or partial blindness.

REPETITION OF THE OPERATION.

With regard to the frequency with which the operation will have to be repeated, much will depend upon the conformation of the mouth, and work which the animal performs. Some need to have the operation repeated every six months to a year; others every two or three years, while others never have to undergo an operation. In some animals the teeth come into perfect wear; in such, an operation is never needed.

It has been found that many animals thrive better and take less feed if their teeth are regularly cared for.

METHOD OF OPERATING.

In order to perform any of the above operations, in fact, any operation on the mouth or head, it is not necessary to cast or confine the animal in any manner except an occasional case. The old idea that a horse had to be cast for almost every operation, I am pleased to say is rapidly growing into disfavor in this country. For this we are

indebted to C. D. House (now deceased), the eminent veterinary dentist, who was the first to operate upon horses' teeth without using a gag or confining the most vicious animals in any manner. As far back as 1875–7 we find Mr. House's mode of operating very unique. He used no gag and left the animals to stand free, passing his hands over the teeth of the most vicious horses without being bitten. Since that time the number using his methods in operating has gradually increased, until at the present time (1889), there are about twenty-five in this country who have become expert veterinary dentists.

In operating, all that is necessary in most cases is to back the animal into a narrow stall, or the corner of a box stall where he can not turn around. The assistant should then place one hand over the nose of the animal, far enough up so that it will not interfere with respiration, either taking hold of the ear with the other hand or placing it over the poll. In this manner he will be able to steady the head and prevent any sudden movement on the part of the horse. For trephining all that is necessary in addition to the above is the application of the twitch to the upper lip. Always handle the animal quietly, allow no boisterous noise or sudden movements. Endeavor to finish the work as soon as is consistent in a workmanlike manner. After the teeth have been placed in satisfactory shape take the bone spoon and

remove all the tartar, finishing up with the brush. The importance of this will become evident after reading the chapter on Salivary Calculi (tartar).

Exercise good judgment in the use of the tooth shears, lest fracture of the teeth take place. There is but little danger of fracture in good sound teeth; but where the teeth are very brittle, as they are in some animals, fracture may readily occur.

PARROT MOUTH.

Parrot mouth is a deformity which is frequently noticed and consists in the upper incisor teeth projecting in front and overhanging the lower incisors. The incisor teeth do not come into wear and as a result they gradually increase in length beyond the gums. In some cases the lower incisors come in contact with the bars in the roof of the mouth lacerating them and eventually producing serious results. The animal will fall away in flesh presenting an emaciated appearance and may eventually die of starvation, even in the midst of plenty.

A horse with a parrot mouth will feed well enough from the manger; but if turned out to pasture, experiences much difficulty in collecting the food.

If the lower incisors wound the roof of the mouth they may be dressed down with the incisor cutters and the rasp. If the upper incisors wound the lower lip they should be operated upon in the same manner.

CHAPTER XV.

DISEASES OF THE LOWER JAW—INJURIES FROM HEAVY CURB BIT.

Disease of the lower jaw sometimes exists which calls for the use of the trephine; such as carious teeth, necrosed bone and superficial fractures where a small portion of bone has been partially or completely separated by external violence.

In using the trephine on the lower jaw great care must be exercised, for the bone here is thin, hard and easily fractured. If the opening by the trephine is made in the lower border of the jaw a five-eighths trephine is as large as should be used. If the opening is made on the side a larger instrument may be employed with safety.

To remove the first, second, third, fourth and sometimes fifth lower molars, the opening for that purpose will be more convenient if made directly under the roots of the tooth. For the sixth and sometimes the fifth the opening should be made into the side opposite the end of the fang of the tooth. It can then be readily driven out with the curved punch in Fig. 51. In trephining for the fourth, fifth and sixth lower molars the opening should not be made indiscriminately. Care must be taken not

to wound either Steno's duct or the submaxillary artery. Division of the former will result in a fistula of the duct and the latter will cause more or less trouble before the hæmorrhage can be stopped. Should the latter condition occur the artery may be taken up and ligated, or it may be twisted and held for a moment when the bleeding will have been completely checked. After the operation of trephining has been completed, should the muscle which has been divided at the side of the jaw close the opening so that the pus which forms cannot escape freely, a portion of it may be excised. The insertion of a large drainage tube will convey any matter which forms, and is perhaps preferable. The tube will have to be removed at each dressing of the wound and if again inserted should be thoroughly cleansed. It is best however to use new tubing at each dressing.

Superficial fracture and necrosis of the lower jaw occurs very frequently and may be due to a variety of causes. On this subject Professor Williams says: "Superficial fractures of the lower jaw occur from severe curbs and bits; anteriorally and from within the mouth from the bit, posteriorally and under the jaw from the curb."

SYMPTOMS FROM INJURIES OF THE BIT.

Dribbling of saliva from or foaming in the mouth. Animal shy or perhaps vicious if the mouth is touched;

inability to bear the introduction of the bit; difficulty in masticating the food; perhaps hemorrhage from the mouth, or saliva streaked with blood. Upon examination the buccal membrane will be found bruised, inflamed and swollen with perhaps a piece of bone sticking through it.

TREATMENT.

Remove the small fragments. As the fracture is superficial no bandaging is required, but the animal must not be bitted until the parts are completely healed and hardened, or he will have a bad or weak mouth ever afterwards; indeed some horses that I have seen never allow a bit to be put in their mouths again without great struggling and resistance. The animal should be fed upon soft diet for some days after the injury and the wound examined occasionally, or portions of bran, hay or corn are apt to lodge in it, causing irritation and retarding the healing process. If the wound discharge a fetid material it should be syringed with a weak solution of carbolic acid; in any case the mouth may be washed with this two or three times a day.

SYMPTOMS FROM FRACTURE BY THE CURB. Swelling and tenderness of ramus immediately in front of the curb; sinuses shortly form, and within them loose pieces of necrosed bone may be detected by the probe. The discharge is curdled, fetid, but not very profuse. In some of these cases there is no

primary fracture, but necrosis of the superficial layer of bony tissue, arising from continued and severe pressure producing periostitis, gangrene of the periosteum, the death of the bone from the pressure and non-supply of blood to that part of it is covered by the gangrenous periosteum. In other cases a bony tumor forms here as a result of periostitis, and of increased thickness of the superficial layer of bone (hyperostosis).

TREATMENT.

In the first and second forms of injury, it is necessary to remove the fragments of bone, whether they are necrosed or not. It is a waste of time to allow them to be removed by exfoliation. The method which I recommend is to slit up the skin, and carefully scrape the diseased surface. If this be done the cure may be effected in a very short time. If the necrosis is very superficial one or two applications of dilute hydrochloric acid will effectually remove it, and render unnecessary the performance of an operation. Common-sense will convince the reader, that the cause, namely the severe curb, must not again be applied.

In the third form of injury, namely, the hyperostosis, all the treatment necessary is the removal of the cause and the application of soothing remedies, succeeded by frictions with iodine ointment.

FIG. 44.

A portion of necrosed bone removed from the lower jaw of a horse.

Fig. 44 represents a piece of necrosed bone which was removed from the jaw of a horse, the property of Burt and Patterson, by the author, September 2nd, 1888. The following symptoms were presented when the horse was brought to the infirmary: There was hanging of the head, eyes partially closed, clear ropy saliva in great quantities flowing from the mouth possessing a disagreeable and offensive odor.

On examining the mouth a large soft puffy swelling was discovered just in front of the first left lower molar. This swelling was soft, pulpy, clear and watery-looking. When I endeavored to press it between the fingers it gave way, a portion of it being easily removed with the fingers. On coming in contact with the bone the piece represented in the cut was found loose. It had entirely exfoliated. After its removal the bone was scraped and thoroughly cleansed with a strong solution of carbolic acid and water. The dressings were continued daily. Recovery took place very rapidly.

The disease was caused by a common bit, the driver having been in the habit of jerking on the rein. All cases of a similar nature do not heal so rapidly; some break out the second and even a third

time, owing to only a partial removal of the diseased bone. To insure success, every particle of diseased tissue must be removed.

Sometimes there are tumors of variable sizes located in front of the first lower molar teeth, which would lead one to suspect superficial fracture or necrosis of the bone. If an abscess forms the matter that escapes will indicate the true nature of the lesion. If it is of a dirty brown color, very fetid, and containing small particles of bone, then we are sure of a diseased condition of the bone, but if from a sub-cutaneous abscess, the discharge will be like that of an ordinary abscess in any other part of the body. If the latter form be present a speedy cure will follow simple dressings and cleanliness. If the former condition be present the case will become tedious unless every particle of diseased bone has been removed.

CHAPTER XVI.

CRIBBING—CAUSES, EFFECTS AND TREATMENT

Cribbing is a condition which may be considered as a vice or habit rather than a disease. It consists in the horse laying hold of any stationary object with the teeth, such as a manger, post, fence, gate, etc., and violently extending his neck, and then after a convulsive action of the throat a grunting sound is heard, accompanied by a gulping in and swallowing of air.

CAUSES.

Many theories have been advanced with regard to the cause of this vice. Some maintain that it is due to indigestion, others to the closeness of the incisor teeth, while some attribute it to a combination of both conditions. Others to idleness. The latter, with heredity, undoubtedly is the main cause and most cases occurring could be traced directly to them if pains were taken to investigate their origin. I can call to mind a cribbing mare whose progeny, three foals to the cover of as many stallions, were cribbers before they were old enough to be put to work. To me this is a clear case of heredity and one which has not been dependent upon

any other circumstances which are calculated to induce the vice. Well fed vigorous colts sometimes get fretful and bite or lick the manger, eventually contracting the habit. With some animals it seems to be natural; they evidently derive much pleasure from the habit.

The effects of cribbing are various. The teeth are worn away and occasionally broken, so much so in aged horses that they graze with difficulty. The grain is often wasted by dropping from the mouth into the manger or upon the floor. Digestion is impaired through the loss of saliva which escapes. The stomach and intestines become distended with gas inducing colic, chronic indigestion and sometimes acute indigestion, lowering the condition of the animal and eventually producing death.

All animals however do not suffer from colic and indigestion; indeed, some remain healthy, fat and sleek notwithstanding they may be addicted to the vice in the severest form.

Wind-sucking constitutes another vice equally as bad if not worse than cribbing. It consists in simply gathering air into the mouth, extending the head, arching the neck, gathering the feet together and gulping down the air. It differs from cribbing in that the animal does not grasp any object with the teeth.

TREATMENT.

Cribbing and wind-sucking constitute a decided unsoundness and are incurable when once thoroughly established. Were the vice due to pressure of the incisor teeth against each other, the extraction of one or two of them would certainly remove the cause and be followed by a cessation of the habit. Some surgeons claim to have entirely dispelled the vice in young animals when first noticed by the extraction of one or more teeth. I have operated in that way (as an experiment), under like conditions on the teeth of several horses, but have never been able to entirely stop the habit. Sawing between the teeth can have no possible effect in breaking up the vice, although it is frequently resorted to for that purpose. A neck strap buckled tightly around the throat while the animal is in the harness will act temporarily in checking the habit, but has no good effect whatever when removed, but on the contrary will press on the throat and produce roaring in some instances.

To prevent the vice give the horse something to do. Do not keep him tied in the stall from one week to another, but turn out and give plenty of exercise.

* "Horses which are crib-biters or wind-suckers are to be considered as unsound, as the vices generally

* Williams' Practice of Surgery, Page 540.

arise from or cause indigestion, induce colic, tend to lower condition and to depress the vital powers.

A crib-biter seizes the manger or some other fixture—the collar-shank when nothing else can be taken hold of—with his teeth, arches his neck and makes a belching noise. After a time the abdomen becomes evidently enlarged. Many crib-biters thrive moderately well, whilst others are always unthrifty, dry in the coat and hide-bound. Some practitioners maintain that air is swallowed during the act, whilst others state that gas is expelled from the stomach, and that the continual belching or eructation causes further derangement of the stomach, the increased formation of gases and the consequent tympanitis. I was at first disposed to think that the first opinion was the correct one, as it is quite possible for air mixed with saliva to be swallowed, but further experience inclines me to the latter; namely, that gases are expelled, and that increased disorder of the stomach are induced by the habit. A chronic crib-biter may be easily recognized by the appearance of the incisor teeth which are worn and rounded at their anterior borders, and by an enlarged or hypertrophied condition of the muscles which depress the jaw, the sterno-maxillaris, stylo-maxillaris, etc., and generally by the mark of a strap on the neck.

A wind-sucker smacks his lips, gathers air into his mouth, extends his head, or presses it against some

solid body, arches his neck, gathers his feet together, and undoubtedly swallows air, blowing himself out, sometimes to a tremendous extent.*

Of the two vices this is the worst; a wind-sucker being more subject to colic, indigestion and polyuria than a crib-biter.

To prevent crib-biting a muzzle or neck-strap made for the purpose is sold by saddlers; and for wind-sucking a strap, studded with sharp points of iron opposite the lower part of the jaw is the best preventative, whilst the indigestion from which these animals seem to suffer is best combated with purgatives, alkalies, rock salt in the manger and regular work. Want of work, indigestion and the irritation of teething are generally the causes of these vices.

† "It is very doubtful whether crib-biting originates from any disease. It may perhaps with more reason be considered a propensity, a habit, or a vice, which in time may result in indigestion, loss of condition, etc. This however, depends much upon the extent to which it is practiced, and the constitutional vigor or strength of the animal; for it is well known that many a horse constantly practicing the vice is neither retarded in his growth nor injured in his health.

* For my part I cannot understand why a crib-biter should only expel gas, and a wind-sucker swallow air. The action and noise made in both cases are similar, as also are the results of the vices. I am inclined to believe from observation that air is swallowed in both instances.

† Dr. H. H. Paaren in *Breeders' Gazette*, Vol. IX, Page 353.

As to the cause of this troublesome vice, it occurs mostly in young horses that are well fed and insufficiently worked. There is no doubt also a special predisposition to the habit; with some horses it appears to arise naturally, as though the sucking or gulping down of air gave them pleasure or a relief from some sort of suffering. It has also been observed that horses at all disposed to it may be easily led into it by the practice of some men in cleaning them; for if they clean them before the manger and irritate them with a too severe comb, and in parts where they can not endure it, they seize upon the manger for a counteraction of their sufferings, and in doing this first get a habit of it which may afterward extend to the removing of other pains or distressful feelings. Some horses indulge in the habit of licking the manger and gnawing the woodwork, which may eventually lead to cribbing.

In practicing the vice cribbers avail themselves of any prominent object even as small as a nail or a ring, and in the absence of any protruding or prominent object they will grasp the halter or bridle-rein. Horses that simply practice the act of wind-sucking, require no resting point. When horses first begin to crib-bite, and sometimes inveterate crib-biters, they only indulge in the practice at intervals, some while eating and others while standing in the stable without food before them. During attacks of pain-

ful diseases, cribbers do not attempt the act, and it may be regarded as a favorable sign when such a horse returns to his old practice.

All sorts of preventatives have been resorted to, including muzzling with steel rods fixed to the bit. The use of a broad leather strap around the throat is not to be recommended because it has got to gradually produce distortion or constriction of the windpipe and thus cause roaring. Our inquirer asks whether placing the horse in a stall devoid of anything upon which to get hold would be a preventative. Well, with the plurality of horses it may; but we have seen some old and inveterate offenders thus placed who practiced the vice upon their knees, and upon the hard floor while lying down."

CHAPTER XVII.

ALVEOLAR ABSCESSES.

THEIR FORMATION, PROGRESS, SYMPTOMS AND TREATMENT

The phenomena attending the formation of an alveolar abscess in the domestic animals, has not yet undergone the thorough investigation it merits. If the pain attending the ulceration and formation of an abscess of this kind is as deep seated, excruciating and almost insupportable, and we have every reason to believe it is, as that of a similar character in the human subject, then it would seem high time that the subject receive more careful attention from the profession and that the owners of stock become acquainted with a true conception of its importance.

It is a fact that alveolar abscesses exist in both upper and lower jaws to a considerable extent.

CAUSES.

The exciting or immediate cause of alveolar abscesses is inflammation of the alveolo-dental periosteum. This may be due to inflammation and suppuration of the pulp or an accumulation of pus at the root of a tooth, the discharge of which is in no other way provided for. It may also be produced by a dead or diseased tooth. External injury brings

about the same results. The accumulation of food between teeth that are placed wide apart, decomposes after a time and gives rise to fetid compounds which have an injurious action upon the parts with which they come in contact. This may be regarded as a predisposing cause. In some animals there seems to be a strumous diathesis which must also, when it exists, be considered as a predisposing cause. This condition no doubt is present much more frequently than is commonly supposed. We know that some animals are predisposed to various bone diseases such as ostitis, bone spavin, ring-bone, etc., and there is no reason why the jaws with their alveolar processes and cavities should not be similarly affected.

The periosteum of a tooth having become the seat of inflammation, all the phenomena attending the inflammation of the periosteum of any other portion of the osseous system will be present. There will be effusion of lymph at the extremity or along the side of the root. This takes the form of a sac or cyst, which closely surrounds the root near its apex, and as suppuration takes place pus is formed in its center. During this time the inflammation gradually extends to the gums and neighboring parts. They swell and become painful. These swellings vary much in size, owing to their situation and the resistance which they encounter. As the pus accumulates in the sac it distends and presses on the surrounding

walls of the alveolus, which are gradually broken down. By this means an opening is ultimately made through the socket, as Fig. 44', when the pus coming

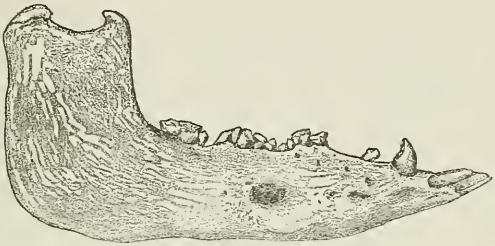

FIG. 44'.
External surface of lower jaw of a hog showing opening formed by an abscess.

FIG. 44.
Table surface of same teeth.

in contact with the soft structures presses upon them and causes their absorption, furnishing an outlet for the imprisoned pus, if in the lower jaw usually externally and inferiorly, if in the upper jaw into the sinus opposite the tooth which is affected.

The opening is usually opposite the tooth. In fact all cases that have thus far come under my observation were so situated; but we can readily understand that the pus may escape from some other and more remote point; indeed such is the frequent

result in the human family when their teeth are affected by ulceration.

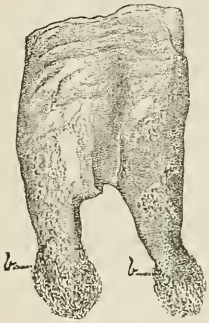

FIG. 45.

First right lower molar tooth showing ulceration of the roots. *b. b.* pus sacs.

Fig. 45 is a drawing made from a tooth showing the sacs brought away with it in extracting, they being the only ones which I have thus far been able to remove intact with the tooth. The membrane closing the cavity usually becomes ruptured, and the ragged edges are all that are noticeable. The sacs, one on either root of the first lower molar were about as large as a good sized pea or bean and contained a fluid with the formation of a small amount of pus in the center.

SYMPTOMS.

The symptoms of alveolar abscess, vary according the location and progress of the disease. There will usually be imperfect mastication of food, "quidding," with loss of flesh, staring coat, with a harsh and unthrifty appearance, and in some instances, greatly emaciated condition of the animal. The gums may or may not be-

FIG. 46.

Table surface of tooth represented in Fig. 45, showing a normal condition.

come swollen, red, hard and painful to the touch. Tapping the diseased tooth lightly produces intense pain.

If there is a tendency for the abscess to break externally, there will be swelling of the parts over the affected tooth, with gradual softening and finally a discharge of fetid pus, which will usually continue until the cause is removed. When the discharge has once freely taken place, the pain partially ceases and the animal begins to feed better and may even regain its natural fleshy condition.

The energy of the disease, however, having been expended, the secretion of pus may cease and the opening into the gums close. There is still a great susceptibility to morbid impressions on the alveolar-dental periosteum, caused by the presence of a tooth deprived of a large portion of its vitality. A recurrence of the inflammation is liable to take place with the slightest cause, when pus will be again formed and the passage for its escape re-established. The subsequent attacks do not give rise to as severe symptoms as the first. By carefully investigating the history of alveolar abscesses, we frequently learn that there has been a recurrence of the abscess. This is especially true in a country practice where there has been limited opportunities to have the teeth looked after by a competent dentist.

In some cases the inflammation instead of subsid-

ing altogether, degenerates into a chronic form with a constant secretion of pus varying in quantity, sometimes profuse at others almost gone. The character of the pus also varies at different times; sometimes it is thin, at others thick. At all times it has a tendency to adhere around the external opening. It is always more or less fetid.

TREATMENT.

Remove the cause. This usually necessitates the extraction of one or more teeth. If due to the accumulation of food between the teeth, its removal should be effected and the parts washed out with a solution of chloride of lime, or carbolic acid, one part to thirty of soft or distilled water. Corrosive sublimate, two grains to one ounce of soft or distilled water makes an excellent disinfectant.

A very singular case of fistulous opening, due to alveolar abscess, was presented for operation at the infirmary during the summer of 1887. The right lower fourth molar was diseased and the abscess had broken on the under surface of the inferior maxilla. By carefully introducing a probe into the fistulous opening, it could be passed completely through the jaw and up along side the tooth into the mouth. The diseased tooth was extracted, and the fistula thoroughly syringed out with a solution of corrosive sublimate, two grains to the ounce of water. Recovery took place very rapidly.

All cases of a similar nature however do not heal so readily. The secretion of pus may cease for a time and the opening close, but whenever the excitability of the alveolar periosteum is increased by any derangement of the system, it is liable to give rise to a recurrence of the disease.

In such instances it is necessary to excise a circular portion of the skin and flesh around the opening. Even trephining may have to be resorted to in order to prevent the recurrence of pus. Trouble of this nature is rarely experienced if trephining is resorted to at the time of the first operation.

While preparing this chapter, I was called upon to operate on the teeth of a four-year-old mare, the property of Mr. Goldsmith, of Lafayette, Indiana, which seemed to be suffering from dental irritation. On making an examination of the teeth, the fourth and fifth lower right molars were found slightly decayed on the external surface of their free portion. The gums were swollen and very tender to the touch. Tapping the tooth with a pair of forceps produced intense pain. A history of the case was given as follows: The mare had been gradually failing for the last eight months, quidding the food all this time. At the time she was presented for operating, she was very much emaciated. A foul, disagreeable odor emanated from the mouth, the result of decaying vegetable matter contained within the teeth. An

attempt was made to remove the teeth with forceps but failed of success. Trephining was resorted to and the tooth was driven out with a punch.

The sides of the fifth tooth were partially covered by a deposition of earthy material, clearly showing that the disease must have existed for a considerable length of time. The sides of the alveolar cavity were in a healthy condition as far as could be ascertained; as a natural consequence they were more or less mutilated with the punch in driving out the teeth, and might have been more or less diseased without showing its effects after the tooth was extracted.

CHAPTER XVIII.

TUMORS OF THE GUMS.

THEIR CHARACTER, CAUSES AND TREATMENT—EPULIS.

The gums and alveolar processes of horses, cattle and sheep, very frequently have developed from them tumors and excrescences of various kinds, varying in character from the most simple growth of the gum to morbid productions of a fungoid or cancerous nature. Some disappear without having ever directed the attention of the attendant, while others are of such a nature that they will not even yield to the most energetic treatment. There is no part of the mouth peculiarly susceptible but they may exist in any portion.

Their character and appearance are variable; some are smooth, others rough and ragged and sometimes covered with ulcers; some have a broad base, others are pedicled; some are soft, others hard and fibrous; some grow so slowly that their growth is scarcely perceptible while the growth of others is exceedingly rapid; some are very vascular while others are almost destitute of blood vessels; some are nearly insensitive while others are highly sensi-

tive, being the source of extreme pain and discomfiture to the animal.

They vary in color from a light gray, almost white to deep purple hue. This is due to the degree of vascularity which they possess, while a good many of them retain the natural color of the gums. Their serious character will depend upon their location, nature and progress, some producing scarcely if any inconvenience, while others produce grave results, in some instances endangering the life of the animal. Some are of sporadic origin others of parasitical.

CAUSES.

Tumors of the gums occasionally arise spontaneously, but most of them can be traced to a definite cause.

They are sometimes due to existing tartar, fractured, loose, dead or decayed teeth or roots of teeth.

Fracture of the alveolar process may follow an operation on the teeth or gums, or by external violence, and set up an irritation sufficient to produce tumors or excrescences of various kinds. Those cases which seem to rise spontaneously, if thoroughly examined would probably reveal the fact that they are of a parasitic or cancerous nature, or could their history be traced, as in the human subject, their causes might in most instances be traced to some form of irritation of the gums or alveolar processes or membrane at some earlier period. It is not neces-

sary to the production of tumors or excrescences, that any of the above causes be actually present at the time they are first noticed. These organs having once been affected they will be more susceptible to morbid impressions.

Of all parts of the body there perhaps is no part that is so thoroughly exposed to irritation from various causes, as the soft structures of the mouth. They are almost constantly subjected to external influences which are calculated to injure them. The nature of the food alone is sufficent to keep up a more or less constant irritation. Gravel, pieces of wood, corn cobs, pieces of wire, sharp ends of hay, all have a tendency to injure the soft structures, with which they come in contact.

TREATMENT.

The treatment will necessarily be varied owing to the many causes which produce the disease. The constitutional symptoms accompanying these tumors will have much to do in adopting a mode of treatment.

By removing the cause, a great many of these growths will disappear, some by simply extracting a dead or decayed tooth or roots of teeth. If they do not subside after the removal of the cause they should be excised; this must be practiced with some care, or severe hemorrhage might follow, especially if the tumors are located over the palatine artery

After the removal of the tumor the place should be powerfully cauterized for the purpose of destroying all sarcomatous tissue and that there may be no recurrence. Paquelin's thermo-cautery is frequently used for this purpose with good results.

If the tumor is again reproduced, the next operation must be made more thorough. The base of the enlargement must be removed. The operation should include the healthy tissue in every direction.

To facilitate the removal of these tumors and insure perfect safety the animal should be cast and securely fastened, the operator having one or two assistants to insure perfect saftey.

Under the designation 'Epulis' Professor Williams says:—"a tumor of the gum often of a simple growth, of the same consistency as the structure from which it grows and not likely to be reproduced when the exciting cause has been removed, and the disease extirpated. Its frequent cause is caries of some parts of the molar teeth. The lower jaw is its most common seat. It commences at the root of the molars, or in the alveolar ridges. The size and extent of epulis are various; it may be confined to the gum between two teeth, or it may involve several if neglected and partake of a malignant character." The disease may exist in two forms: the benign and malignant. In his description Professor Williams says that the former is smooth on the sur-

face and of slow growth, and seems to be unattended with pain but from its size interfere with mastication. The latter is ragged, of rapid growth, frequently bleeding and giving the animal much pain and is accompanied by infiltration into the surrounding bones *and* hard palate, of the characteristic cancer-like matter.

The following case of a tumor in the dog is taken from the *American Veterinary Review:*

*MAXILLARY FISTULA IN A DOG.

BY MR. X. PAUCHENNE.

A pointer slut had on the right facial region a tumor the size of a nut, somewhat soft and painful. Opened it allowed the escape of a certain quantity of clotted blood, which was squeezed out and the neoplasm was dressed externally with tincture of iodine. After a few weeks the animal entirely recovered. Three months after, however, there was a relapse and the growth had reappeared with the same character. Remembering the mention of similar cases made by Prof. Reul, of the Bruxelles school, the author made a careful inspection of the buccal cavity and examined with attention the condition of the molar teeth. Percussing every one with the point of a pair of curved scissors, he observed that the third molar, though like all the others presenting a handsome white appearance, gave a pecu-

*American Veterinary Review, Vol. 10, Page 517.

liar sound, and seemed to be less strongly implanted in its alveolar cavity. This tooth was extracted and found to be slightly decayed under the gums. It was the cause of the trouble, for recovery rapidly followed the operation and the animal has enjoyed perfect health since.

CHAPTER XIX.

NASAL GLEET.

CAUSES, SYMPTOMS AND TREATMENT—TREPHINING—STEPS IN THE OPERATION—AFTER TREATMENT.

Nasal gleet is a sub-acute inflammation of the membrane lining the frontal and maxillary sinuses of the head. It may be due to various causes. The only ones however, that we shall consider are those that require surgical aid to induce partial or complete recovery.

CAUSES.

Caries of the upper molars, the third, fourth, fifth and sixth especially; elongated inferior molar teeth which wear the gums and alveolar processes of the upper jaw, inducing caries; hypertrophy of the fangs of the upper molar teeth; exostoses on the fangs; external injury; disease of the facial bones; collections of impissated pus; foreign substances passing up through a cavity in a carious tooth's cystic tumors; calcarious concretions in the maxillary and frontal sinuses; clots of blood in a state of decomposition; straw, chaff, hay, etc., which accidentally pass from the nostril into the sinuses; or even whole teeth passing up into the sinuses.

SYMPTOMS.

There will be a discharge from one nostril only in a majority of cases. This discharge varies much in quantity, being almost entirely absent at times, at others very profuse. It does not adhere to the border of the nostrils. It usually sinks in water. If it contains particles of bone; it has a fetid odor as well as the breath that comes from the affected side. If the teeth are unsound it can be easily detected by making an examination of them. They also give off an offensive odor when carious. If the disease is of long standing there may also be bulging of the walls of the sinus. When the sinuses or their divisions are filled with pus, percussion applied to the outer walls causes a dull sound to be emitted. If there is any doubt about the confinement of pus in the cavity the introduction of a small gimlet or drill, will when withdrawn, contain pus in the groove if there be any present.

The symptoms of this disease are sometimes mistaken for those of glanders and many animals suffering from nasal gleet have been killed for glandered animals. Such mistakes however, are the result of ignorance of the characteristic symptoms of the two diseases.

While preparing this chapter I was sent to investigate a supposed outbreak of glanders in a black gelding. The animal presented the following symp-

toms: great emaciation, dejected appearance, staring coat, listlessness and a disinclination to move about. There was a discharge from the right nostril of a greenish yellow color mixed with blood (the animal had just been fed hay and also allowed to pick a a small quantity of grass), very fetid, slight abrasions of the mucous membrane lining the nostril. The discharge contained small pieces of hay and grass, some of which could also be seen well up in the nostril.

On making an examination of the teeth I found the right fourth upper molar partially decayed and presenting a deep cavity. This cavity had connection with the maxillary sinus. The tooth was removed by trephining, the horse making a rapid recovery.

TREATMENT.

Remove the cause, then make an opening at the most dependent part of the sinus, allow the pus to escape and inject the cavity with warm water containing a small amount of carbolic acid or common salt. This injection may be effected with a common syringe or an injection pump, the latter being preferable as it throws a constant stream and does not irritate by being constantly inserted and again withdrawn in order to be refilled. Too much force should not be used for the mucous membrane is very tender and sensitive. A common rubber tube may

be used with one end inserted in the opening made by the trephine and the other containing a funnel into which a constant stream of water can be poured, or the tube may have one end attached to a pail which is suspended over the head. The dressings should be repeated once each day until the cavity closes, care being taken not to injure the mucous membrane of the sinus.

The following cases show the necessity of making a careful examination before ordering the destruction of a horse because he is supposed to suffer from glanders.

*"There are instances on record of carious teeth being discovered and of their being productive of such consequences as have led, through error, to fatal termination. The following relation ought to operate on our minds as a warning in pronouncing judgment in cases of glanders, or at least in such as assume the semblance of glanders.

A horse the property of the Government became a patient of Mr. Cherry's on account of a copious defluxion of fetid discolored purulent matter from the near nostril, unaccompanied either by submaxillary tumefaction or by ulceration of the Schneiderian membrane. For two or three months the case was treated for glanders, but no amendment appearing a consultation was deemed necessary, the result of which was the horse was shot.

*Percival, Hippopathology, Vol. II, Part II, Page 297.

On examination of the head the third molar tooth proved to be carious, one-third of its fang being already consumed and the remainder rotten. The formation of an abscess within its socket had rendered the tooth loose and the matter flowing therefrom had established a passage into the contiguous chamber of the nose. The antrum, also, was in part obstructed by the deposition of osseous matter. This is a case which but for the inquisitiveness of Mr. Cherry, would have indiscriminately merged into that heterogeneous class of diseases passing under the appellation of chronic glanders.

* Surgeon William Smith, of Norwich, England, reports a case of caries of the roots of several grinder teeth, accompanied by a discharge from the nostril which he admits he mistook for ozena. He says (*Veterinarian*, 1850, Pages 381-2):

"I was requested a few days ago to visit a horse which was supposed to be 'glandered'. I found the animal in a most emaciated and pitiable condition, with a copious, greenish, and very offensive discharge from the left nostril with slight tumefaction of the gland on the same side. There was no appearance of ulceration, but the Schneiderian membrane had a leaden, dirty hue. Taking all the circumstances into consideration, I ordered the animal's destruction, but had its head sent to my infirmary.

*Clark, Horses' Teeth, Page 182.

"Meeting Surgeon Gloag, of the Eleventh Hussars, I told him I thought I had a case of ozena. He expressed a wish to be present at the examination of the head, and I was glad to avail myself of his assistance.

"A longitudinal cut was made on each side of the septum nasi and a transverse one at a line between the center of the orbits. Another longitudinal cut, dividing the maxillary sinuses was made just above the roots of the grinder teeth on each side. By this means we had an opportunity of examining the septum nasi on each side; also the turbinated bones and the frontal and maxillary sinus.

"On the left side we found an accumulation of food, covered with thick pus, completely filling the maxillary sinus, and extending to the turbinated bones. The frontal sinus contained an accumulation of inspissated (thickened) pus, the septum nasi was of a leaden hue, as also the membrane covering the turbinated bones, which were much inflamed and thickened, but there was no appearance of ulceration.

"The difficulty was to ascertain how the food got there. After careful search it was very evident that it could not have passed through the nostril. We therefore gradually dislodged the food and matter, searching for the former's entrance, and at last found a hole in the alveolar space belonging to the last grinder, the root of which was completely gone,

only a small portion of the crown itself remaining. The hole was sufficiently large to admit the little finger. The mystery was solved. The process of mastication had deposited the food in the sinus. The fourth grinder was absent, having been lost evidently from previous disease.

"On examining the right side of the head, we found the turbinated bones and membranes covering the septum nasi comparatively healthy, but we discovered a cyst, about the size of a walnut in the maxillary sinus. It contained limpid fluid, and occupied the space immediately over the root of the fourth grinder tooth, which was decayed and quite loose and *below* * the level of the other teeth. The teeth of the lower jaw appeared healthy."

"Without further examination, Surgeon Smith sent the head to the Editor of *The Veterinarian* who says:

"The mare (that being the sex according to the teeth), we should take to have been about twenty years old. Her incisors are sound and so are the grinders of the lower jaw. But in the near (left) upper jaw, the second, fourth and sixth teeth are in a state of progressive decay, and the same is true of the fourth tooth on the off side. The vacuity caused by the defective last grinder has opened a passage to the antrum through which the food has passed, and

* Italics Clark's.

thence into the rear chamber of the nose, between the turbinated bones, where it was discharged through the nostril. This accounts for the irritation on this side of the head, for the suppurated and even ulcerated condition of the Schneiderian membrane, and for the suspicious discharges. It was evident enough that there was no glanders. The very circumstance of alimentary matter being discharged through the nostril was enough to prove the contrary."

*AMERICAN VETERINARY COLLEGE HOSPITAL RECORDS.

CARIES AND REMOVAL OF THE THIRD UPPER MOLAR TOOTH —SUPPURATION IN THE NASAL TURBINATED BONES—TREPANATINE—RECOVERY—BY JAMES A. WALRATH, D. V. S., HOUSE SURGEON.

On the 19th of August a brown gelding was admitted to the hospital with the following history: Toward the latter end of April the owner's attention was called to a slight discharge taking place from the right nostril of a whitish character, which was observed to be more abundant when the head was depressed.

Thinking it to be nothing more than a simple nasal catarrh he concluded that no treatment was necessary and kept the animal at work, supposing that the discharge would cease spontaneously. After a delay of some weeks without any perceptible

*American Veterinary Review, Vol. X, Page 317.

change he, by advice of friends, sent the horse to the country for a run at grass. Here he remained, as the owner supposed, doing well, until word was received from the pasture, the owner announcing that the services of two practitioners had been called to see the animal and that there was a question in dispute between them as to the nature of the disease with which the animal was suffering. One maintained he was affected with glanders and ought to be destroyed, while the other one contended that it was not, and that the discharge was due to other causes, which were not in the least contagious. Immediately after this the horse was sent back to the city and a short time after his arrival was brought to the hospital for examination. At this time the discharge was not very abundant, being flaky in character and having a peculiarly bad odor. A large swelling was visible on the right side of the face, involving the nasal bone, especially in its superior portion, percussing dullness was well marked, not alone over the swelling, but over nearly the whole extent of the bone. The animal reared when moved, respiration not being performed without considerable difficulty.

Examination of the nasal cavity with a reflector showed the mucous membrane to be of a leaden color, and the turbinated bone to be enlarged and quite prominent, even at the inferior extremity, which was readily noticed by lifting up the wing of

the nostril. Placing the hand in the mouth of the same side, the third molar tooth of the upper jaw was found to be decayed and the cavity partially filled with undigested food. After proper preparation of the animal by dieting, he was thrown down, and while under the influence of chloral, the diseased tooth was extracted by removal in two pieces. The bulging nasal bone was then trephined, and about two ounces of cheesy pus taken from the sinus of the turbinated bone with a spoon probe. He was then allowed to get up, and the sinus thoroughly cleansed with luke-warm water from a small pipe which was inserted through the opening made by the trephine, the water that entered being allowed to escape through the nostrils, carrying with it small pieces of detached pus.

This treatment was kept up twice daily until scarcely any discharge was noticed, after which the irrigations were not as frequent, taking place but once per day, and later on still rarer, the opening being kept open with a short firm tent of oakum, and the granulations around the edge cauterized frequently with nitrate of silver.

After the discharge had ceased the oakum was removed from the opening and the edges allowed to unite, union taking place very rapidly.

The tooth cavity was kept as clean as possible after the extraction, by washing out with water the

foreign matters that daily collected. The function of respiration which had been mechanically interfered with was, after the operation, performed with ease, and at the end of the fourth week he was discharged. He has been seen since several times, and found in perfect condition, doing his daily work.

TREPHINING—STEPS IN THE OPERATION.

The operation of trephining may be divided into three separate steps: 1st, the securing of the animal; 2d, the removal of the soft structures; 3d, the removal of the hard structures.

1st. Back the animal into a narrow stall, apply a twitch to the upper lip and have it held by an assistant. Another assistant should place one hand across the nostrils, high enough up so as not to interfere with respiration, and the other hand across the poll to prevent the animal from making a sudden movement. To trephine successfully, it is not necessary to cast the horse, especially if he has never been operated on before. There are, however, instances where it is necessary to cast the animal, but they are exceedingly rare. In four years' practice as a professional dentist, I have never found it necessary to cast but one animal, and that one had been operated on several times previous to my operating.

2d. It is advisable to remove a circular piece of skin and subcutaneous tissue somewhat larger than the trephine. Dissect away all the soft structures,

removing every particle, or the trephine will become clogged. A common scalpel, Fig. 47, may be used for making an incision through the skin, and if it has a straight, thin bone or ivory handle, the soft structures including the periosteum can be easily removed by pushing the end of the handle underneath them and raising them up. Some operators prefer a crucial incision, others a T incision. If either of the latter forms of incision are made, the opening, as a general thing, will close too soon. The flaps also interfere with the washing and dressing of the sinuses; they sometimes become swollen and very painful to the touch. By making the circular incision, the operation is more readily performed and the edges of the wound do not interfere with the dressing.



FIG. 47. Operating Scarpels.

3d. The removal of the bony plate is accomplished by the use of the trephine, of which there are several kinds, all of which will do good work as long as they are kept sharp. At present they are all made with a center bit. The other instruments necessary are a scalpel, a strong pair of dressing forceps and a sequestrum forcep, Fig. 49, with which to remove the piece of bone when it is not brought out by the trephine. The bit should be extended one-fourth inch beyond the saw of the trephine; this,

when inserted, will hold the saw in position. If the operation of trephining is resorted to in order to effect the removal of a tooth by punching it

Galt's Trephine, Nickel Plated.

Trephine Handle,

FIG. 48.

out, the opening should be made directly over the roots of the tooth. Should there be two teeth side by side which require a like operation, an opening made with an inch and a quarter trephine directly

FIG. 49.

Sequestrum. Forcep.

over both teeth, will be sufficiently large to admit of the punching out of both teeth through the same opening. If a smaller trephine is used, and it is desirable to increase the size of the opening, it can be done with the separating saw. Fig. 50.



FIG. 50.

The punches used in driving out teeth are of various sizes and shapes, but should always be large enough to cover all the roots of the tooth on which it is used. They may be made of hard wood, iron

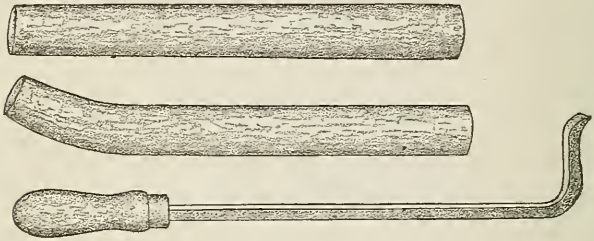

FIG. 51.
Straight and Curved Punches and Curved Elevator.

or steel; about six inches long and round or octagonal. The punches which I use are made of steel, polished, and correspond in size with the trephines,

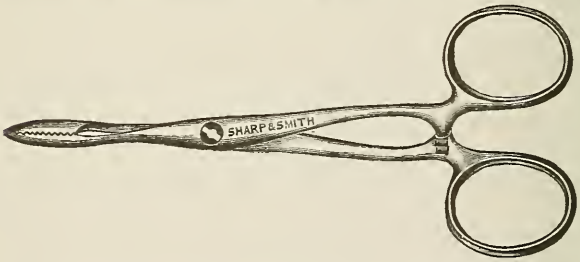

FIG. 52.
French Snap Forceps, for holding arteries.

which are four in number varying from five-eighth to one and one-fourth inches. These punches for the most part are straight. Where the opening with the trephine is made, as in Fig. 15, a curved

punch will be necessary in order to get under the teeth. Such a punch is represented in Fig. 51.

FIG. 53. Elevator and Raspatory.

AFTER TREATMENT.

Keep the parts clean and dress daily with warm water containing a small quantity of carbolic acid or common salt. Be careful to remove all foreign substances contained in the cavity. Keep the wound open as long as there are any indications of existing disease of the sinus, or until the alveolar cavity which contained the tooth that has been removed, fills up with a healthy growth. If the operation is performed during the season of the year when flies or other insects are liable to keep up an irritation, the opening may be covered with a piece of cloth secured in place with pine pitch or some other adhesive substance. A plug of carbolized tow or oakum inserted in the opening will answer the same purpose in addition to keeping the wound open.



FIG. 54. Right Angle Elevator.

It is not necessary to plug up the opening left by the extraction of the tooth except perhaps in occasional cases.

CHAPTER XX.

OSTEO POROSIS.

This disease may affect any or all portions of the osseous system, often involving the teeth, and it is this fact that has led me to consider the subject in this work. The teeth frequently become so loose that they can be drawn out with the fingers. Dr. Weese, of Ottawa, Ill., relates a case where all the superior molars were loose with but little enlargement of the facial bones. Such cases frequently occur, and in order to properly diagnose the condition it is necessary to understand the disease. It would be of no use to operate or extract the teeth of such animals, as the disease is not amenable to treatment and the animal so affected sooner or later succumbs to the disease.

Dr. Anderson, of Macon, Ga., who has made the subject a special study, read the following paper before the Illinois Veterinary Medical Society, November 16, 1888:

"It is more with a view of directing the attention of the veterinary profession, rather than casting any light upon the etiological or therapeutical phase of the disease, that I offer this article on the

above named subject to this able veterinarian assemblage. And furthermore should I, before its conclusion, venture upon its etiology, I wish it understood that the idea is merely a hypothesis; as the true causes of this strange affection are at the present one of the many unsolved pathological problems, and it is not my intention to present positively other than facts.

"The subject is one of great importance, as the proportions which it has assumed in some parts of this country are simply alarming, and with our present knowledge of the disease we are unable to take any steps towards its prevention.

"Various are the titles by which it is known, seeming to have gained them from the ideas which those who assumed its nomenclature, had of its morbid anatomy or parts involved. And the name which I here accept under which to describe it, seems to me inappropriate, as it neither indicates the true pathological condition, as we shall see presently, or gives any idea as to the cause. In India it is known as the 'Nasal Disease' and has been described under this title from time to time, by veterinarians in that country in their communications to various veterinary journals. It was first recognized in England about the year 1859 and is described by William Williams in his works, under the title which this article bears.

SYMPTOMS.

"While in that section of the United States where it is most prevalent, it is spoken of as 'Big Head,' 'Big Shoulder' and 'Big Jaw,' the three terms designating its supposed location only. The disease itself is characterized by the formation of bony, tumorous appearing enlargements in the facial region, at point of shoulder and in the rami of the inferior maxilla, associated usually, but not always, with a general unthrifty appearance; pulse but little if any altered; constipation rather a constant symptom, respiration undisturbed, visible mucous membranes may or may not be paler than normal, and the body temperature but little or none above the standard. The appetite usually remains good and after the progression of the disease lameness of a peculiar kind is evinced, while an almost ever present symptom is the extremely small quantity of water drank. So marked is this particular feature that those in charge will usually acquaint you with this fact upon first consultation.

The disease seems to exist in two forms; acute and sub-acute or chronic. Williams in classifying this affection in his work on "Principles and Practice of Veterinary Surgery," places it under the head of non-inflammatory osseous diseases, but in describing it presents phenomena in its course of development and post-mortem appearances which corre-

spond to those of inflammation, and which could not possibly exist without inflammatory action. It is therefore an inflammatory disease as we shall plainly see, and not a non-inflammatory one, as he classifies it. In his accounts of post-mortem appearances which agree in part with those held by myself and others he says, referring to the bones: 'The periosteal covering of the flat and irregular, and also some parts of the long bones, was very vascular and could be easily stripped off.' Again as regards the cartilages he writes: 'In most instances although not in all, the articular cartilage was of a dark slate color, much thinner than is natural, and in many places it was entirely lost,' while in another section pointing to membranes, we find the following, reading thus: 'The synovial membrane was considerably thickened, especially in those parts where it is most vascular.' At the beginning of his post-mortem report we find this quotation: 'On his attempting to walk, his fore legs gave way at the elbow joint on one side and shoulder joint on the other, in consequence of the articular and capsular ligaments and tendons of the muscles becoming detached from their bony connections by tearing away of portions of diseased bones.'

These quotations are sufficient I should think, to convince the most skeptical without further argument, as to its inflammatory nature. In its descrip-

tion I shall first consider that form in which the enlargements appear in the facial regions, but not from the fact that the disease is located wholly here, as is thought by many, for 'tis false; but solely on account of some interesting features which are associated in animals presenting the facial enlargements which, by the way, rarely diminishes the caliber of the nasal chambers enough to interfere with respiration. The enlargements will be found situated principally within the maxilla and below the orbit, obliterating in most instances that concavity which marks the junction of the superior maxilla with the nasal bones, causing the face when viewed from an affronting position to appear more like that of an elephant than of the animal to which it belongs. In gathering the history of this class of subjects you will find that nothing important has made itself manifest that would lead to the suspicion of the existence of a disease so grave in its character, beyond the appearance of the enlargements, together with slight thickening of the inferior maxilla; provided they were rapid in their course of development and were not of long standing; and even then, in some instances they, with the inferior maxilla, are the only marked evidences during life. This is a peculiar fact, since every bone in the body is at this very time more or less involved. On the other hand, should the enlargements prove slow to develop, and

the disease had progressed far enough, you would find the history of the case quite different, and your subject presenting if the form was acute, considerable constitutional disturbance with an elevation of temperature, visible membranes injected, constipation present, feces altered in color, respiration accelerated, with lameness of a peculiar kind; and if located around those joints not well protected by muscles giving attachment to tendons, heat, swelling and tenderness upon pressure will exist to a degree. These latter symptoms are due in all probability to rupture of some of the tendinous fibers from their bony attachment, while the partial removal of the articular cartilages which occurs, is sufficient to account for the lameness.

Again, if the animal affected does not develop at all the facial enlargements, the first symptoms made manifest usually are of the most acute kind, shown by extensive tumefaction around the joints, with evidence of positive rupture of tendinous attachments; complete possibly, and probably, fracture or rather a tearing away of some part of the bone itself, which occurs in all probability from muscular contraction or undue weight being thrown upon it. The proximal end of the humerus will show considerable enlargement, constituting 'Big Shoulder,' as it is termed, and if the fèmur could be outlined, would present the same changes. In fact, it is in

this form of the disease that the long bones, and those too which possess the greatest amount of cancellated tissue are most affected, as shown by the extensive tendinous rupturing which occurs only partially, if at all, in those subjects developing the facial enlargements early and rapidly.

The rami of the inferior maxilla will be found much larger than in other instances, and it will be important to here state that this bone in all cases invariably gives evidence of the existence of the disease, by an increase of its transverse diameter when no other symptoms are sufficiently developed to testify to its positive existence. The solution of this at first seemingly strange fact is easy, since we know this bone to possess the greater amount of cancellated tissue of any, where examination is not prevented by its protection of muscular tissue. The superior maxilla together, I will repeat again, with every bone in the osseous frame, hyoides included, are at this very time affected, but do not show evidence from the reason already given. Indeed, it is a disease peculiar to bone only, and you should not be misled by the rupturing of the tendons and muscles, as this is due to the necrosed condition of the bones at the points of their attachments, and not to any altered condition of their fibers. If the maxillaries are much affected and the molar teeth be examined, especially the upper, by placing the fore-

finger and thumb upon one, each on opposite sides, and pressing them inward, it will be found that the bone can, to some degree, be compressed, causing pain, a condition which is mistaken by many and thought by them to be due to loosening of the same within the alveoli. An animal thus affected finds difficulty in eating, and is apt at any moment in his movements to rupture tendons from their attachments, or the bones themselves may give way on the animal rising from a recumbent position or taking a false step. I have seen instances in which the metacarpals and metatarsals were fractured by the animal stepping from a box stall to the passage-way floor, which was not more than six inches below that of the box.

POST MORTEM.

One interesting case which I will give (instead of citing many), of a pony which did not show evidence of the disease other than the rami enlarged transversely, and a short groggy gait while being ridden by a boy, stumbled and fell upon his left side on a dirt road which was rather soft. When he arose it was found that he had fractured the scapula crosswise above the tubercle of the spine. On being destroyed a few days later, the autopsy revealed nothing important as concerned the internal organs, but on examining the bones it was found that the periosteum was easily detached from most of the

surfaces of all the bones, and particularly so in that part of the bone where the greatest amount of spongy tissue existed. Their extremities were greatly increased in their transverse diameter, their shafts were not much affected in this way, presenting after divestment a pinkish hue. Upon pressure being applied ever so slightly bloody fluid would ooze from the bony substance, which when the pressure was released would recede again into the tissue showing the porous condition which existed. To the touch they were soft, velvety, elastic and slightly rebounding. The articular cartilages were somewhat discolored but all intact in this particular subject, which probably accounts for the absence of lameness other than that to which I have already alluded. In these cases showing continual, decided lameness, the cartilages will be found not only discolored, but removed by absorption in part or wholly. A section made into a long bone at its most affected part, which was done with little resistance, showed the canal somewhat increased transversely, with its contents of a reddish, watery character. The haversian canals and cancelli were in some instances obliterated, with their traversing blood vessels excessively engorged, while the lacunæ and canaliculi were filled with a light yellowish semi-fluid substance. Both the large and periosteal foramena were dilated and the periosteum

thickened. The weight of the bones was greatly increased owing to the amount of fluids present, but when allowed to dry they became extremely light and if their surfaces were not interfered with presented a furry appearance, steel grayish in color, which would if the finger was drawn lightly across it receive an impression like that made upon plush. I did not further examine these specimens but am satisfied from their condition that animal matter existed in preponderance; which is self evident, and not inorganic material as our writers ascribed.

It is not a disease of growth as is thought, for in my observations I find it affecting the equus family under all circumstances, without regard to age, sex or habits of life. We also find its subjects both plethoric and anæmic. Plethora existing only in that form in which the facial enlargements develop rapidly. I have never known other animals to become its victim, but one of our writers however, describes it in sheep. The horse seems to become attacked most often while the mule is rarely affected, even in that country where the disease is most prevalent and they are used almost exclusively.

CAUSES.

It has been attributed to various causes, and among them to errors of diet. G. H. Dadd now deceased, who was formerly of Chicago, Illinois, and who evidently gave the matter a great deal of

thought, (his investigations extending over that country bordering on the Ohio River), in his works on equine diseases expresses himself as being of the belief that its cause is probably traceable directly to the feeding of Indian corn. But this idea is an erroneous one, as we find it existing in animals that never received a grain of maize. The same author is also of the opinion that it may have an hereditary origin as he says: "Unless this be the case we cannot account for its universal prevalence." Here again he is in error, and had he noted the formation of those localities in which he found it to be most prevalent, although universal as he terms it, I think possibly his opinion would have been altered. I shall not attempt myself to speak positively on this part of the subject, but will give the history of a few cases and leave you to draw your own conclusions:

Case 1. In the fall of 1883 there was shipped from the western states, a three-year-old colt, to a malarial district of one of the Atlantic bordering states; she being richly bred was intended for track purposes. Her food consisting principally of hay, oats and bran, best quality grown in the west, for all such provender used in the cities in that country, is shipped from that section. Grass was given to her each day after her work and the water given was obtained from a cistern which was filled by the water shed from the roofs of the neighboring build-

ings. The quarters were good as regards the building, while the care taken of her could not have been better. After six months' stay, she developed the disease in its sub-acute form, but recovered partially without treatment and lived some years afterwards.

Case II. In another instance there were a number of horses shipped to a gulf bordering state, intended for track purposes also, and receiving their food from the same source; the quantity and kind corresponding for each, and likewise with that in the case of the colt, but the water was obtained from a well on the premises. One of the number developed the trouble in an acute form by midwinter, which by the way is very mild comparatively in that country, and recovered partially afterwards. I knew of the occurrence in a sucking colt, running in a pasture with its mother which gained her existence from the grasses which the field afforded, and watered at will from a stream crossing one corner of the lot. The colt made a partial recovery but was unfortunate enough to die from a kick inflicted by a companion in its two-year-old form.

Case III. There is a private barn in one of the southern cities which was erected in 1844, on the borders of a large marsh lying within a few hundred feet of its doors. It contains six horses which are used daily for draft purposes, their food being hay, oats, corn and bran, and the water is obtained from

the city reservoir from which the entire inhabitants are supplied. In three months after occupying their new quarters, an eight-year-old gelding, which had been in the city upwards of two years, fell a victim to this disease in its most acute form; and the proprietors have been unfortunate enough to lose one or two from the same cause each year since.

When in communication with that excellent gentleman and veterinarian, Alex. Harthill, Jr., of Louisville, Kentucky, who has given this subject a great deal of thought and investigation, I learned of him the history of cases corresponding to those already given. I mention this fact merely, not wishing to enter into further details, so as to intimate corroborating observations as gathered from another whose experience extends over a longer period.

These few examples I hope will suffice, and by them it has been plainly shown that the quantity or quality of food or water or season of the year has nothing to do with the production of the disease; but you will observe that the home of the affection is in a *malarial* country and is most prevalent where the circumstances are the most favorable for the development of vegetable micro-organisms. Again you will notice that during the existence of the circumstances seemingly, under which it was produced, *partial repair* takes place through nature's efforts and that this partial repair may occur

in subjects where it develops either of its forms, while from the autopsy and other evidence you will note the products to be evidently the result of a primarily localized irritant. And that the irritant is *confined to the blood vessels* permeating the bones, producing inflammation which runs through its various stages, causing the different morbific changes which we find existing. I have said nothing concerning its transmission, either from breeding an infected animal or by infection, but do possess evidence pro and con for the latter.

*CHAPTER XXI.

FILLING HORSES' TEETH.

It is only of late years that the filling of the teeth of our domesticated animals has been in practice.

When I first commenced the practice of veterinary dentistry I think it was almost unheard of. I began to see the need of it more and more every year as my practice increased and experience grew larger.

I have repeatedly watched teeth with small cavities and seen them grow larger until the caries extended to the pulp cavity, when extraction was the only alternative.

The thought often came to me that these teeth might be saved if properly filled, yet I did not attempt the operation until after attending lectures on human dental surgery.

I have met with varying success, but think now that in cases where caries has not gone too far, that many teeth may be reclaimed and do the animal years of good service. Filling the teeth of animals is only practical when caries first commences, as the nerve is so large that I think it impossible to destroy it and remove it successfully and if it is not well done it is better not done at all.

*This chapter was prepared by Dr. Sayre, D. V. S,

From my present knowledge and experience I do not think it practical to attempt to fill other than the incisors and the first three molars, as I have found it impossible to get light and room sufficient to operate back of that; in fact it is extremely difficult to fill the third molar.

In writing this short chapter I have made use of Taft's Operative Dentistry and The American System of Dentistry, which I would recommend to the student who desires to make himself proficient in this branch of dental surgery.

As our knowledge increases we will see the importance of this operation more, and I predict that in a few years filling horses' teeth will be a common practice. It is the only treatment we have recourse to in caries. By it the disease is checked and the lost part restored to usefulness as nearly as possible by any foreign substance.

If properly and skilfully performed the operation is successful in preserving teeth which would soon have to be extracted. We cannot restore lost parts as the human dental surgeon can, for various reasons. The food is too hard. Take, for instance, a molar, with say half of the crown gone. In the human tooth it could be built up and stand the wear, but in our subjects, in which the process of mastication is carried on almost entirely by the lateral motion, it would dislodge the filling in the first place, and wear it out in the second.

INSTRUMENTS FOR FILLING.

In describing the instruments used in filling, I will take them in the order in which they are used, first referring to those used in examining or exploring the cavity, then those for cutting and dressing off borders, removing

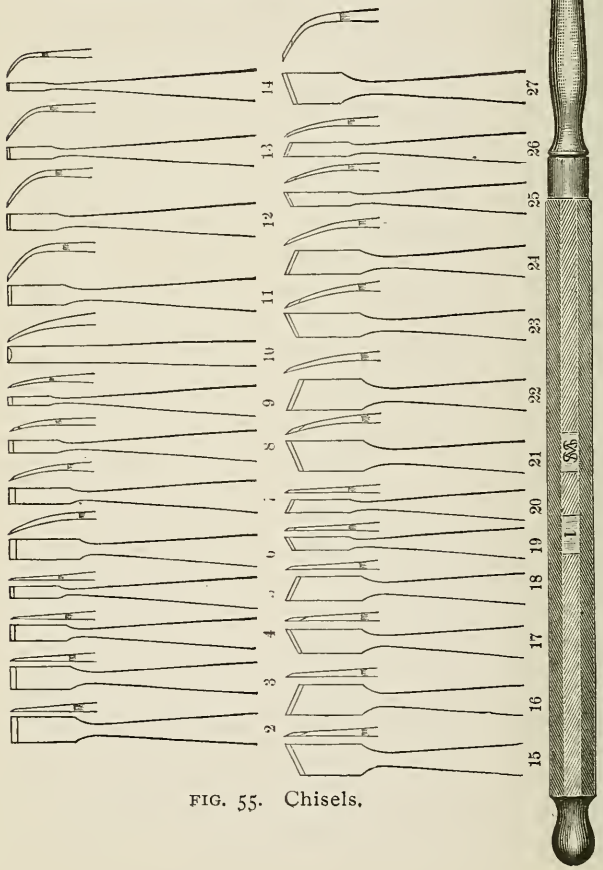

FIG. 55. Chisels.

decay and forming the cavity, and finally those for introducing, consolidating and finishing the filling.

EXPLORING INSTRUMENTS.

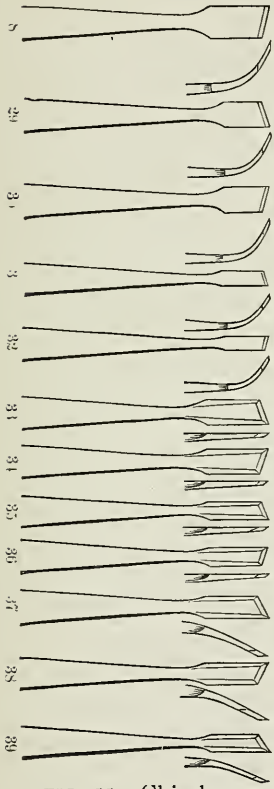

FIG. 55. Chisels.

For this purpose we use the small excavators used in human dental surgery. There are an endless variety of forms manufactured for this purpose.

CHISELS.

These are strong cutting instruments used in opening cavities and cutting off projections of dentine and enamel and cutting down the sides of the cavity, Fig. 55.

Of these the dental surgeon should have a large variety of sizes and shapes, as it is with them that almost the entire cavity is formed.

The dental engine has almost wholly superseded the use of hand drills in human practice, and the veterinary dentist is even more dependent upon it, as it is impossible to use hand drills in cavities in some of the molars, because

the mouth cannot be opened wide enough, they are easily drilled out with the engine by using the



FIG. 56, Hand Burs and Drills.

hand piece, which operates at an angle of about 45 degrees.

Fig 56 shows a variety of drills, the cone, round and bud being the ones most used, the inverted cones



FIG. 56. Hand Burs and Drills.

being used in cavities in the molars which are sometimes made larger at the bottom than at the orifice.

FILLING INSTRUMENTS.

AMALGAM, GUTTA-PERCHA AND PLASTIC FILLING INSTRUMENTS.

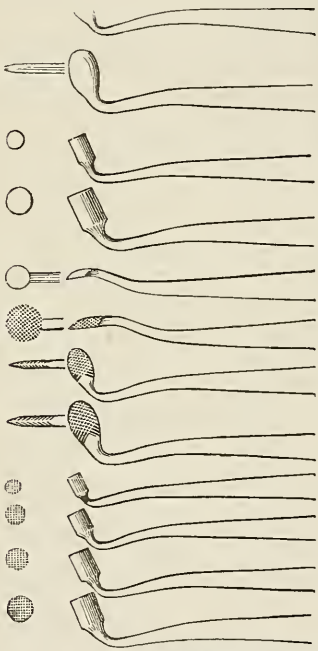

FIG. 57. Dr. B. F. Arrington's Amalgam Pluggers and Burnishers.

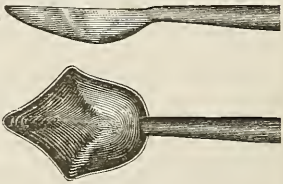

FIG. 58.

FIG. 57.

Fig. 57 represents Dr. B. F. Arrington's set for the introduction of amalgam, gutta-percha and cement fillings, and I think it is the best set of pluggers for the veterinary dentist.

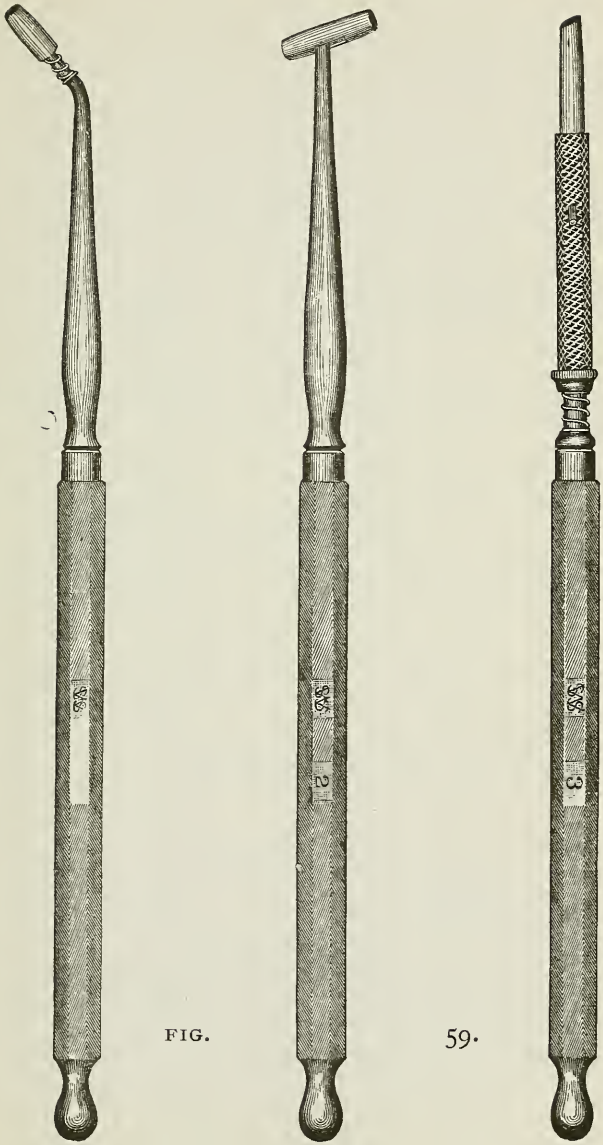

FIG. 59.

Fig. 58 is a very convenient instrument for carrying the amalgam to the cavity.

There are a number of carriers and fillers which are very convenient in filling.

No. 1 is Dr. Thomas Fry's which has a fixed point covered by a projecting tube, thus forming a

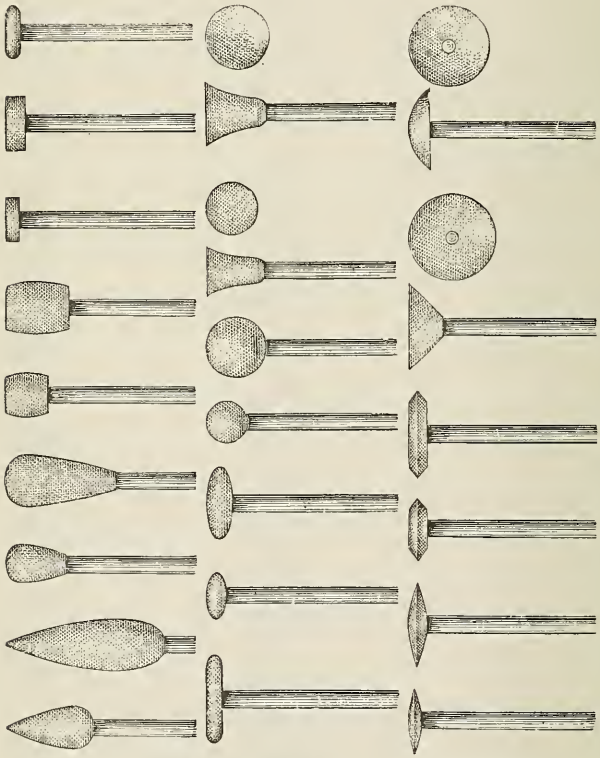

FIG. 60. Arkansas, Hindostan and Scotch Stones.

cup which recedes on pressure so that the point forces the amalgam into the cavity. No. 2, Dr. W. S. Elliott's, and No. 3, Dr. W. B. Miller's are operated in the same manner.

Fig. 60 represents a set of corundum points, cones and disks for finishing and polishing fillings; these are on short stocks to be used with the engine. The same forms are made of Arkansas, Scotch and Hindostan stone.

MATERIALS FOR FILLING.

Of the materials used in filling teeth, I will only describe those that I think best adapted to our purpose.

Amalgam. This is rather a broad term applied to all the preparations formed by combining mercury with various other metals. Those most commonly used are silver and tin, but occasionally gold, zinc, lead, platinum and cadmiun.

"The kind most in use is prepared by melting together and carefully mixing pure tin and silver, and filing this when cooled, into dust, combining the latter with mercury in sufficient proportion to give the requisite plasticity, and then thoroughly washing the whole in alcohol or boiling water to remove the oxides formed during the combination of the metals"—(Taft.) I like this the best for filling the teeth of animals as it is easily and quickly introduced and is the most durable.

Gutta percha is useful for temporary fillings, or fillings where there is not much wear, as cavities in the labial surface of the incisors. It is very easily introduced; all that is necessary is a spirit lamp to warm it until it becomes plastic or it may be immersed in boiling water, when it will readily conform itself to the cavity.

FILLING THE TEETH.

Having considered the instruments, materials and cases in which filling is practical, we will now proceed with the operation, first taking the incisors and then the molars.

Here we labor under difficulties which the human dental surgeon does not have to contend with; our patients will not come to our office and sit in a chair with head in any position desired; on the contrary, we have to work in almost any position to suit him; or confine him, which I dislike to do and only find it necessary in filling the molars.

I find in operating on the incisors that a gag is very convenient. It should be about eight inches long and three inches in diameter, with a hole about an inch from each end, through which a clothes line is passed and over the top of the head to retain it in the mouth. Around this I wrap a rubbing cloth to protect the bars of the mouth from injury, and it will also absorb a great deal of saliva. If we are going to operate on the lower teeth we

will wrap another cloth about them to keep them dry.

Having our patient ready, we must first give the teeth a thorough examination. This should not be hurriedly done, for on it the subsequent work depends. For this purpose we should have a large variety of fine pointed instruments, so curved and formed as to be easily brought in contact with all parts of the tooth, so as to detect any defect that may exist.

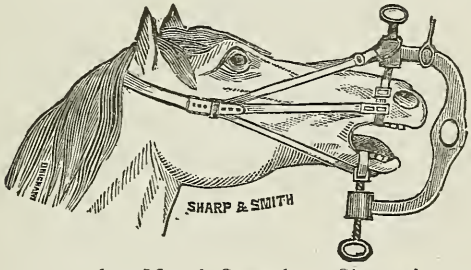

FIG. 61. Mouth Speculum, Simons'.

For this purpose we use the small exploring instruments.

To open the cavity we will use the bur drill and large chisels (Fig 56 and 55), using the chisel to cut down the sides of the cavity. This may be done by hand or with the mallet. The drills are used in the bottom of the cavity. The fine drill should always follow the chisel to smooth and even up the surface cut.

In our subjects it is best to remove all decayed portions.

In operating on the human tooth the decayed portion is not always entirely removed. In cases where the dentine is entirely decomposed down to the pulp, when by its removal the pulp would be exposed, it is thought by some operators that the decayed dentine gives better protection to the pulp than any artificial covering.

By others it is thought that the decayed dentine being in an abnormal condition, will irritate the pulp and in many cases destroy it.

The ultimate destruction of the pulp and tooth seems the most rational consequence of confining the decayed dentine in the cavity. In my opinion the decayed dentine, being in a diseased condition, acts as a fountain head of disease, and filling over it is like trying to stop a train going down grade without putting on the brake. "Yet cases are cited where fillings have been introduced into cavities at the bottom of which a portion of softened dentine covered the pulp, and on removal of them in from one to five years afterward, all parts were found to be equally and normally dense." (Taft.)

Whether decayed dentine covering the pulp should be removed or not, I will leave each student to decide for himself.

There are some particulars in which all operators agree: First—That all decomposed dentine should be removed from all parts of the cavity when the

pulp would not be injured thereby, and especially from the lateral walls and the orifice.

In removing the decomposed dentine such instruments should be selected as would seem best adapted to the purpose.

In cutting, the direction should be from the nearest point of pulp exposure toward the orifice of the cavity.

In removing decomposed dentine we must not forget that the cavity must be so formed as to retain the filling when properly introduced. To do this it is most always necessary to remove more or less solid dentine to secure suitable retaining points.

"In large cavities where one side of the tooth is weak, places must be selected for making retaining points that will least affect the weak point." (Taft.)

There are several ways of forming retaining points. Under-cutting and grooving is practiced by some, others preferring to drill little holes or pits into the dentine, these taking effect in different directions.

After the cavity is formed and before introducing the filling, it must be thoroughly dried with bibulous paper and the warm air blow pipe.

This instrument is made of a small blow pipe, with a cylinder about two inches from the point. This cylinder is made of some heavy metal, so as to retain heat. On the other end is an india-rubber ball,

To manipulate the instrument, first heat the cylinder, then by pressure on the ball with the thumb a current of hot air is forced into the cavity, which has been first dried with bibulous paper. This soon dries it perfectly, the walls of the cavity becoming white as it dries. We now have our cavity ready for the introduction of the filling.

In preparing amalgam for introduction, put a sufficient quantity in a mortar, add mercury sufficient to give the requisite plasticity, and then wash thoroughly to remove the oxide formed during the combination of the metals.

The excess of mercury can be removed by pressing the paste in a piece of chamois or between the thumb and finger with a rolling or rocking motion. After the mercury has been pressed out, break up into small pieces and insert into the cavity pressing down each piece firmly until the cavity is full, when it should be finished with the corundum points or disks, Fig. 60, and followed by the burnisher. Burnishing is done by rubbing the round smooth surface over the filling until it is perfectly smooth and bright.

In filling the molars the same course is followed, but we find it often necessary to cast the animal so as to obtain light, and confine the head in position suitable for work; we also find it necessary to use a speculum to keep the mouth open. There are a

large variety of these in the market, Dr. E. A. A. Grange's, being probably the best, Fig. 61. In drilling out the cavities in the molars we have to depend almost exclusively on the dental engine, as the hand drills cannot be used in the mouth. The hand piece referred to before Fig. 56, operating at right angles, or Fig. 57 operating at an acute angle, are the only instruments with which cavities back of the first molar can be made. In preparing the cavities great care should be taken to obtain suitable retaining points; in the molars we can leave the cavity larger at the bottom than at the orifice, dove-tailing it as it were. This form retains the filling well, but great care must be exercised in filling, to have it pressed firmly against the walls of the cavity so as to support them, otherwise they will be crushed in.

CHAPTER XXII.

DETERMINATION OF THE AGE OF THE HORSE, OX, SHEEP, PIG AND DOG.

DENTITION IN THE HORSE.

The teeth are the only means at our command by which we can determine the age of the domestic animals in a scientific manner. For years this subject has been treated by various authors. Drawings have been made, I might say from time immemorial, a great many of them the result of a vivid imagination, others true copies of them; or they may have been slightly altered to suit the fancy of the author. When we compare these drawings with what actually exists in nature, we notice a vast discrepancy in a majority of cases. Observation on the teeth of the living animal, is the only means by which we can become adepts at determining the age of the domestic animals.

At birth the foal has two central temporary incisors, either in sight or covered with a thin membrane which disappears by the fourth or fifth day. They are always partially covered when through, the anterior portion of the tooth only protruding.

The 1, 2, 3,* molars are also completely covered

*See Fig. 15.

by the gums at birth, but make their appearance in from one to five days.

At two weeks the central incisors will be well up and the extreme corners of the lateral incisors will be visible under the gum, and are through about the third or fourth week. At six to eight weeks both pairs as well as the temporary molars are well up and the foal able to masticate solid food. The central incisors have their surface very slightly worn, the infundibulum not yet being entirely surrounded by structures which have come into wear. The wear of the lateral incisors is confined to the anterior edge nearest the central teeth.

From two to seven months no perceptible change in the teeth is noticed, except that those already up increase in size bringing the whole of their table surface into wear. Sometimes however, the posterior border of the incisors do not come up even with the anterior border until later.

At from seven to eight months the anterior border of the corner incisors may be seen protruding through the gum. At nine months they are entirely through, with their anterior edges even with the edges of the other incisor teeth. A triangular space posteriorly and externally will still remain out of wear.

The fourth molar, which is permanent, now makes its appearance and by the end of the first year is even with the temporary molars but has not yet

come into wear. This when it can be examined is almost positive evidence as to the age.

If the mouth of a colt be closely examined at from six to nine months, small spicules of bone, or more properly teeth, will be noticed making their appearance just back (and at the same time) of the corner teeth; these are the deciduous or temporary canine teeth. I have never noticed them in a filly. They are shed in the course of a few weeks, usually by the time the corner incisors are up and in wear.

If the colt is large and well developed, it may at this age be mistaken for a two-year-old, for the incisor teeth are very much alike at one and two years of age.

The incisor teeth of a yearling somewhat resemble those of a five-year-old. No one, however, could mistake a yearling for a five-year-old, unless it be among the ponies which have to shift for themselves, in which the general appearance of youth is quickly lost; such is said to be the case in some instances with the ponies on the western plains.

At about eighteen months the fifth molar, permanent, begins to protrude or can be felt immediately under the gums. At two years it is level with the other molars, but not yet worn away on the table surface.

At two years the incisors all have their table surfaces in wear, with the exception of an occasional

case, which yet retains more or less of the triangular depression on the posterior borders of the corner incisors.

Between two and three years of age begins that change in the dentition of the horse which often becomes a source of annoyance. Some animals grow thin and do not again pick up in flesh until the fifth year is reached. At this age the central temporary incisors are replaced by permanent teeth. Soon after two years there will be signs of shedding of these teeth. The gums surrounding the necks of these teeth are somewhat sunken and more or less congested. A red line is noticed surrounding the teeth, and it is evident all but a small portion of the roots have been absorbed.

At two and one-half years the temporary teeth will have been pushed off and the permanent ones appear. These permanent teeth are easily recognized by their general appearance. They are much wider than the temporary teeth, about half grown, with deep cavities on their posterior border. At this age they are only about half developed, consequently there is considerable space between the upper and lower central incisors, when the mouth is closed.*

At two years and eight months to two years and nine months the anterior border of the table sur-

* The teeth of the lower jaw usually precede those of the upper jaw by several weeks, and are the ones examined in determining the age.

face will have come into contact. At three years these edges have come into wear, but not the posterior edges. These edges do not come into wear until from eight months to one year later.

At two and one-half years another important change is taking place. The first and second temporary molars are shed and replaced by permanent teeth. They are up and in wear by three years to three years and two months.

From the third to the fourth year the lateral incisors make their appearance in the same manner as noticed in the central.

The third molar is replaced by a permanent one at three to three and one-half years, and the sixth molar makes its appearance as a permanent tooth.

At four years the lateral incisors have their anterior border in apposition. The posterior surface has not yet come into wear. The third and sixth molars are level or nearly level with the other molars. The tusks, canine, or "bridle" teeth usually make their appearance at the fourth year, but are not fully developed until the horse is five to five and one-half years old. They have no value in determining the age of the animal, their period of cutting being exceedingly variable. In the mare there are usually no canine teeth developed; should they however, be present they are small and blunt and do not make their appearance until a later period, about the sixth or seventh year.

The corner incisors are all the temporary teeth remaining at this time. At four to four and one-half years they are replaced by permanent teeth.

At the fifth year the anterior border of the corner incisors meet, the triangular space on the posterior surface of these teeth yet remains and is very characteristic of a five-year-old. The tables of the lateral incisors are now fully formed, the central cavity being surrounded by a line of worn surface. At this age a horse is said to have a full mouth.

If we carefully examine the above facts we can see some reason for the oft repeated statement: "I had rather work a three than a four-year-old horse, for they can better stand the work." Between the fourth and fifth years the dental changes are the cutting of four permanent incisors, four canine and eight molars making sixteen teeth which are all growing at one time. Is it a wonder that the animal often suffers severely and is unable to take much solid food?

After the fifth year the age of the horse is determined by examining the cavities and general appearance of the (lower) incisor teeth.

At six years the cavities of the corner incisor teeth are completely surrounded by a line of worn surface.

The central incisors have their cavities partially worn out. Their boundaries however are distinctly marked by the central enamel with which it is sur-

rounded. These cavities are nearer the posterior than the anterior edge of the tooth. The depression on the internal surface of the tusks is yet well defined.

At seven years the table surface of the corner teeth are perfectly formed and the cavity in the tooth very shallow. The central enamel is eliptical and nearer the posterior than the anterior border of the tooth. The cavities of the lateral incisors are oval and nearly worn out of the tooth. In the central incisor the central enamel is triangular. The tusks are somewhat worn, giving them a blunted appearance.

At eight years the central enamel of the central incisors is triangular in form and near the posterior border. The table surface also begins to narrow from side to side. The central enamel of the lateral incisors is triangular and the cavity nearly obliterated.

At nine years the central enamel of the central incisor teeth is round and near the posterior border. The lateral incisors have the central enamel oval and near the posterior border. That of the corner is triangular and the cavity nearly obliterated by wear.

After the ninth year the age of the horse can not be accurately determined, but there are general appearances which will assist in arriving at the approximate age of the animal.

At ten years the central enamel of the central incisors has disappeared, and that of the lateral incisor is round and near the posterior border. The central enamel of the corner incisors is oval.

At eleven the central enamel of the lateral incisors has disappeared, and that of the corners is round.

At twelve the central enamel of the corner incisors has disappeared.

At thirteen the table surface of the central incisors has become triangular.

At fourteen the table surface of the lateral incisors are triangular.

At fifteen the table surface of the corner incisors is triangular.

At sixteen the diameter of the table surface, from before back, exceeds the lateral diameter in the central incisors.

At seventeen the diameter of the table surface, from before back, exceeds the lateral diameter in the lateral incisors.

At eighteen the diameter of the table surface, from before back, exceeds the lateral diameters in all the incisor teeth.

Gray hair around the eyes and over the face, and depressions behind the orbits, are indicative of advanced age and help one to form a pretty correct idea of the age of the animal. Sometimes fraud is

resorted to in order to deceive and cover up the marks of old age. False marks are made on the table surface of the teeth. This is known as "bishoping." The gray hairs are painted, called "gypping." The depressions above the eyes pricked and blown up with air. This is known as "puffing the glym."

DENTITION IN THE OX.

The teeth of cattle and pigs are not so regular in their appearance and changes as those of the horse, hence they can not be relied upon to give the same degree of accuracy. This is due to the manner in which they are kept. Cases of extraordinary development of the dentition in these animals have been noticed at the late Fat Stock Shows. They no doubt were due to the method of feeding resorted to, in order to produce early maturing animals. Cattle which are reared for purely dairy purposes do not shed their temporary teeth and complete dentition at as early an age as do the beef breeds; nor are the processes of dentition as variable in the former as the latter. The mode of dentition which I shall describe is founded upon observation among various members of the Holstein breed of cattle.

The teeth, as indicative of the age of the ox, is not to be depended upon after the fifth year, but up to that time the regularity with which they make their appearance and changes, form a fair basis by which to judge the age of the animal.

The incisor teeth of the ox are eight in number, and all located in the lower jaw.

At birth, all the incisors and temporary molars (1, 2, 3,) are so far advanced that they may be seen under the gums, and by the end of the first month are through and fully developed. These teeth retain about the same appearance, and no accurate opinion can be formed from observation until the sixth month, when the fourth molar (permanent) makes its appearance.

At one year and six months the fifth molar appears.

At one year and eight months to two years the central incisors are shed and replaced by permanent teeth, which are much wider and larger in every respect than the temporary teeth. Somewhat later, the sixth and last molar makes its appearance, and is fully developed by the second year.

Up to this time, should an error arise with regard to the age of an animal, through the examination of the incisors, it can be corrected by examining the molars.

At two to two and one-half years, the first and second molars are replaced by permanent teeth, which are up and in wear at three years of age. The third molar is replaced by a permanent tooth about six months later.

At from two years and four months to two years

and six months, the first intermediate (internal lateral) incisors are shed and replaced by permanent teeth, which are up and in wear at three years.

The third pair of incisors or second intermediates (external lateral) are shed at three years and replaced by permanent teeth, which are up and in wear at four years old.

The cutting of the corner incisor is variable, indeed as much so as the canines in the horse, and very little reliance can be placed upon their appearance. They may appear anywhere from three and one-half to four and one-half years. They always are up and in wear by the fifth year. All the teeth at this time show worn table surfaces. Dentition is always more advanced in bulls (and the better bred the earlier the process of dentition is completed) than in steers or females. After the fifth year the teeth form no true basis by which to judge the age. If the cattle have horns, the age can be calculated from the appearance of the rings on the horns. For the first two years the rings are so indistinct that the first ring indicates a three years' growth, and by adding one year thereafter for each ring, we get the correct age, so that an animal with four rings would be six years old, an animal with six rings eight years old, and one with eight rings ten years old.

DENTITION IN THE SHEEP.

At birth the lamb is usually without incisor teeth,

but they are visible under the gum. The centrals make their appearance first, and are rapidly succeeded by the other pairs in their order, so that by the fourth week they are fully developed. At eighteen months the central incisors are replaced by permanent teeth, which are up and in wear at two years old.

At two years the first intermediate (internal lateral) are shed and permanent teeth take their place. These are up and in wear by the third year.

From three years to three years and two months, the second intermediate (external lateral) are shed and replaced by permanent teeth, which are up and in wear by the fourth year.

From three years and nine months to four years and three months, the corner incisors are shed and permanent teeth appear, which are up and in wear by the fifth year.

The changes which take place in the dentition of the molar teeth are relatively the same as in the ox.

DENTITION IN THE PIG.

The pig is born with eight temporary teeth, the corner incisors and the tusks. At three to four weeks the first incisors make their appearance, and at eight weeks the second incisors are cut. At one month the first four molars are cut, and are temporary, with the exception of the first, which is permanent. At nine months to one year the corner

incisors and tusks are shed and permanent teeth take their place. At twelve months the central incisors, at thirteen months the third and fourth molars, at fourteen months the second molar, and at eighteen months the lateral incisors, are replaced by permanent teeth. At five months the fifth molar is cut as permanent, at nine months the sixth and at eighteen months the seventh molars appear as permanent teeth.

DENTITION IN THE DOG.

The dog is born with the eyes shut; they open about the ninth or tenth day after birth. The whole of the milk teeth are cut by that time or shortly after.

At one year to one year and three months the 'nferior incisors begin to wear, and the space between the upper central begins to widen.

At eighteen to twenty-four months the central incisors are much worn, and from two to two and one-half years the lateral incisors are worn; at three to four years all the incisor teeth, both upper and lower, show much wear. After this, the general appearance of the teeth, their bluntness and yellow color, will assist in forming some idea as to the age of the animal.

TABLE OF DENTITION

IN THE

DOMESTIC ANIMALS.

Incisors.	Horse.		Ruminants.		Pig.		Dog.	
	Eruption.	Change.	Eruption.	Change.	Eruption.	Change.	Eruption.	Change.
Central	At or a few days after birth.	2 to 2½ yrs.	At birth.	1½ to 2 yrs.	3 to 4 weeks.	1 year.	4 to 6 weeks.	3 to 4 months.
Lateral	About 4 wks.	3 to 3½ yrs.	At birth.	2½ years.	5 weeks.	1½ years.	"	"
External Lateral	About 4 wks.	3 to 3½ yrs.	10 to 14 days.	3½ years.	5 weeks.	1½ years.	"	"
Corner	7 to 9 mos.	4 to 4½ yrs.	2 to 4 weeks.	4½ years.	At birth.	9 months.	"	5 months.
Tusks, or Canine	4 to 4½ yrs.	4 to 4½ yrs.	2 to 4 weeks.	4½ years.	At birth.	9 months.	"	5 to 6 mos.
Molars, 1	At or a few days after birth.	2½ yrs.	At birth.	1½ to 2½ yrs.	7 weeks.	5 months.	3 to 4 months.	"
" 2	"	2½ yrs.	"	1½ to 2½ yrs.	8 days.	14 months.	4 to 5 weeks.	"
" 3	"	3 yrs.	"	3 years.	8 days.	13 months.	"	"
" 4	9 to 12 mos.	"	6 months.	"	13 months.	"	"	"
" 5	18 to 20 mos.	"	1½ years.	"	5 months.	"	4 to 5 mos.	"
" 6	4 to 4½ yrs.	"	2½ years.	"	9 months.	"	5 to 6 "	"
" 7	4 to 4½ yrs.	"	"	"	18 months.	"	5½ to 6½ "	"

INDEX.

PAGE.
Abscess, Alveolar 181
Age of the Horse, by means of Dentition 240
Age of the Ox, by means of Dentition 248
Age of the Sheep, by means of Dentition 250
Age of the Pig, by means of Dentition 251
Age of the Dog, by means of Dentition 252
Anatomy of the Head 7
Anatomy of the Teeth 15, 26
Canine Teeth, Deciduous 34, 40, 42
Caries of the Teeth 72, 76
Caries of the Teeth—How diagnosed 74
Caries of the Teeth—Progress of 75
Caries of the Teeth—Symptoms of 78
Caries of the Teeth—Effects of 80
Caries of the Teeth—Treatment 87
Cribbing 174
Cysts, Dental 124
Dental formula of Horse 54
Dental formula of Ox 60
Dental Neuralgia 119
Dental Cysts 124
Dental Cysts, Williams 129
Denuding of the Teeth 88
Denuding of the Teeth, Causes 91
Denuding of the Teeth, Treatment 92
Dental Pulp 19
Dentine 16
Dentition, Temporary in the Horse 31, 33
Dentition, Temporary in the Ox 35
Dentition, Temporary in the Dog 39
Dentition, Temporary in the Pig 41
Dentition, Permanent 50

PAGE.
Dentition, Permanent formula of 51
Dentition, Cough of 66
Dentition, Table of 253
Diseases due to Dentition 61
Diseases due to Dentition, Symptoms 65
Diseases due to Dentition, Williams 71
Enamel 16
Exostosis 94
Exostosis, Cause 95
Exostosis, Character 102
Exostosis on the walls of Sinus 104
Exostosis, Treatment of 102
Exostosis, Varieties of 102
Epulis 192
Filling Horses' Teeth 224
Filling Horses' Teeth, Instruments for 226
Filling Horses' Teeth, Materials for 238
Foreign Substances 115
Fractures of the Teeth 119
Fractures, Superficial of Lower Jaw 168
Fractures by the Curb 170
Glanders 196
Gleet, Nasal 195
Gums, Tumors of 189
House, C. D 123
Incisors 31, 33, 36, 37, 39, 40, 42
Lampas 135
Maxilla, Superior 7
Maxilla, Inferior 11
Molars, Temporary 31, 33, 39, 40, 44
Molars, Permanent 55, 58
Nasal Gleet 195
Teeth, Extraction of 55
Teeth, Fractures of 119
Teeth, Incisors 20, 21, 31, 33
Teeth, Irregular wearing of 157
Teeth, Molars 20, 25, 21
Teeth, Number in Horses, Ruminants, Dogs and Pigs 20
Teeth, Projecting in Horses 139

PAGE.
Teeth, Projecting in Sheep 150
Teeth, Projecting in Pigs 153
Teeth, Temporary, their removal 69
Teeth, Temporary Molars 31
Teeth, Temporary Incisors 31
Teeth, Temporary Canine 31
Teeth, Wolf 25, 51, 67
Trephining, Steps in 205
Trephining, After Treatment 209
Treatment of Caries 87
Treatment of Denuding of the Teeth 92
Treatment of Exostosis 96
Treatment of Alveolar Abscesses 186
Treatment of Tumors of the Gums 191
Treatment of Nasal Gleet 196
Tumors, Cystic 131
Tumors of the Gums 84
Wolf Teeth 25, 51, 67

CHICAGO

VETERINARY COLLEGE.

FOUNDED 1883.

THE COLLEGE BUILDING,

Which has just been Remodeled Throughout and Extensively Enlarged, is

The Most Complete of its Kind

ON THE CONTINENT.

Regular session commences October 1, in each year.

For Prospectus and full particulars address the Secretary,

JOSEPH HUGHES, M. R. C. V. S.

2537 & 2539 State Street,

CHICAGO, ILLINOIS.

SHARP & SMITH, Chicago, Ill.

Send for Illustrated Veterinary Catalogue.



All Goods made by our Most Experienced Workmen.

Conkey's Set of Veterinary Obstetrical Instruments,

CONSISTING OF

ONE EXPELLER, ONE CURVED KNIFE, ONE SAW,
ONE BLUNT HOOK, ONE SHARP HOOK,
ONE HANDLE TO FIT ALL.

ESTABLISHED 1844.

THE LARGEST AND OLDEST SURGICAL AND VETERINARY INSTRUMENT HOUSE IN THE WEST.

SHARP & SMITH,

Manufacturers and Importers of

Superior Surgical and Veterinary Instruments,

73 RANDOLPH, ST., CHICAGO, ILL.



Fig. 64. Farmer Miles' Ecraseur.

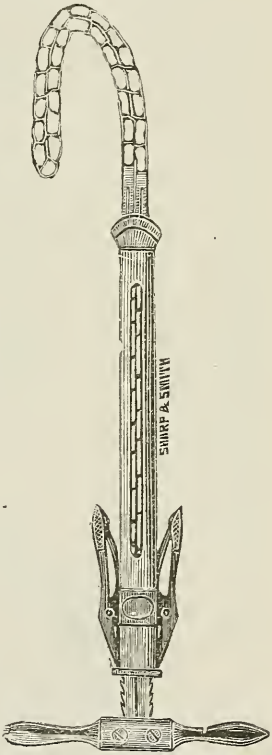

Fig. 63. Chassaignac's Ecraseur.

Send for Illustrated Veterinary Catalogue.

SHARP & SMITH, CHICAGO, ILL.

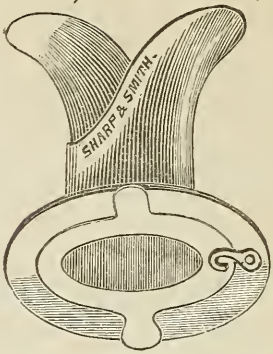

Fig. 151. Tracheotomy Tubes, Self-Retaining.

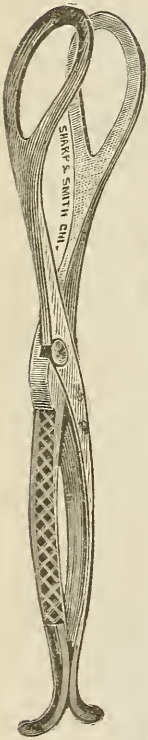

Fig. 89. Pig Forceps.

Fig. 59. Burton's Improved Drenching Bit.

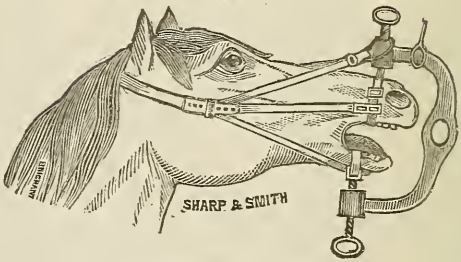

Fig. 58. Simons' Mouth Speculum.

All Goods Warranted.

Send for Illustrated Veterinary Catalogue.

OCT 7 1927

DATE DUE

OCT 1 7 1996		OCT 2 5 1996	
	OCT 3 0 1996	NOV 2 0 1996	

Demco, Inc. 38-293